

# Anesthetic Management for Pediatric Liver Transplantation in a Patient With Propionic Acidemia: A Case Report

Journal of Investigative Medicine High  
Impact Case Reports  
Volume 9: 1–4  
© 2021 American Federation for  
Medical Research  
DOI: 10.1177/23247096211015025  
journals.sagepub.com/home/hic  
 SAGE

Luis I. Rodriguez, MD<sup>1</sup>, Erica J. Tainsh, MD<sup>1</sup>, Eliane Varga, MD<sup>1</sup>,  
and Ana C. Mavarez, MD<sup>2</sup>

## Abstract

Propionic acidemia is an inborn error of metabolism characterized by accumulation of propionic acid due to deficiency of propionyl-CoA carboxylase. Main stay of treatment focuses on reducing dietary protein. However, orthotopic liver transplantation decreases the frequency of metabolic decompensations and improves life expectancy. We report a case of a 4-year-old boy undergoing orthotopic liver transplantation to treat propionic acidemia. This case highlights the use of intraoperative monitoring of metabolic markers like urine ketones, arterial ammonia, and lactate levels as these patients are at risk for hyperammonemia and metabolic acidosis. Also, the relevance in outcomes when performing early extubation in fast-tracking recovery.

## Keywords

propionic acidemia, pediatric liver transplantation, pediatric anesthesia, pediatric metabolic disorder

## Introduction

Propionic acidemia (PA) is a rare, but life-threatening, inherited metabolic disease that results in deficiency of the mitochondrial enzyme propionyl-coenzyme A carboxylase.<sup>1</sup> Prognosis is usually poor, as patients experience metabolic decompensations that result in organ dysfunction. Patients with PA can benefit from liver transplantation,<sup>2</sup> but are at risk of metabolic decompensation during the procedure. Frequent monitoring of ammonia, lactate, and urinary ketone levels throughout the procedure is key to proper management.<sup>3</sup> Whenever possible, extubating prior to leaving the operating room (OR) may fast-track the recovery of these patients.<sup>4</sup>

## Case Presentation

A 4-year-old male, 14.5 kg and 85.5 cm, with PA diagnosed when he was 3 days old. Patient initially presented with lethargy and decreased oral intake. Laboratory workup at that time resulted in elevated serum ammonia level and increased urinary ketones. Genetic laboratory testing was performed, which revealed him to be homozygous for the PCCB (propionyl-CoA carboxylase subunit B) gene mutation. He had several more episodes of hyperammonemia in his first 2 years of life, but each resolved with carnitine treatment at home, which accelerated ammonia elimination. He was fed with low-protein formula and supplemented with

L-carnitine. He had global developmental delay, for which he received speech therapy, occupational therapy, and physical therapy. He was followed-up by genetics, gastroenterology, and a nutritionist. Due to decreased oral intake, he was gastric tube feeding dependent. No metabolic crises had occurred within the year prior to the transplant.

The patient was listed for orthotopic liver transplantation (OLT) to treat PA. Preoperative evaluation and workup for liver transplantation included a computer tomography scan of the abdomen, an ultrasound of the liver, and an echocardiogram, which were all normal. On admission, blood was drawn for baseline laboratory levels, which included total and free carnitine, acylcarnitine profile, plasma and urine amino acids, ammonia, urinalysis, and a complete metabolic profile, which were all within normal limits. As per the pediatric gastroenterology and genetics

<sup>1</sup>University of Miami, Miami, FL, USA

<sup>2</sup>Augusta University, Augusta, GA, USA

Received November 20, 2021. Revised March 19, 2021. Accepted April 12, 2021.

## Corresponding Author:

Ana C. Mavarez, MD, Department of Anesthesiology and Perioperative Medicine, Children's Hospital of Georgia, Augusta University, Medical College of Georgia, 1446 Harper Street, Suite BT-2649, Augusta, GA 30912, USA.

Email: amavarez@augusta.edu



specialists, the patient continued his home dose L-carnitine but intravenous (1.4 g IV) as an inpatient, and was started on IV parenteral nutrition with dextrose 10% at 1.5 times maintenance plus appropriate electrolytes and intravenous intralipids at 2 g/kg/day.

Intraoperatively, patient underwent IV induction with propofol (50 mg), glycopyrrolate (0.2 mg), and cisatracurium (4 mg) via a 22-gauge peripheral IV, followed by uneventful endotracheal intubation with a 4.0 endotracheal tube. Central venous access was obtained under ultrasound guidance to the right internal jugular vein with a 5 Fr, 10 cm catheter and a right radial arterial line for frequent blood sampling and intraoperative real-time blood pressure monitoring. Following intraoperative discussion and recommendation from genetics, IV total parenteral nutrition infusions and intralipids were continued intraoperatively at the same rate, and a bolus dose of IV L-carnitine was given before incision (0.7 g IV bolus over 3 minutes). Additionally, an IV insulin infusion was started at 1 unit/hour after induction, and adjusted based on patient's serum glucose levels (target glucose levels: 100-200 mg/dL). Urine ketones, blood ammonia, glucose, and an arterial blood gas were checked every hour and corrected accordingly. Urine ketones were normal throughout the case.

After induction, baseline laboratory tests were drawn, which revealed a normal pH, lactate level of 3.6 mmol/L (normal range = 0.5-1 mmol/L), serum ammonia level of less than 9  $\mu$ mol/L (normal range = 21-50  $\mu$ mol/L), and negative urinary ketones. During the anhepatic phase, the lactate level increased to 4.6 mmol/L and serum ammonia level increased to 25  $\mu$ mol/L, and both normalized after liver reperfusion. Urinary ketones remained negative throughout the case. Sodium bicarbonate (0.5 mEq/kg) boluses were administered during the anhepatic and post-reperfusion phase to correct metabolic acidosis. He was hemodynamically stable throughout the case and did not require any vasoactive drugs or experience any significant clinical decompensation. Total amount of fluids administered were 2 L of crystalloids and 250 mL of albumin 5%. The total blood loss was approximately 50 mL, and urine output was 250 mL. Duration of surgery was 292 minutes. He was extubated after the surgery was finalized in the OR and was transported to the pediatric intensive care unit (PICU) without any vaso-pressors in a stable condition. He spent a total of 5 days in the PICU during his postoperative course.

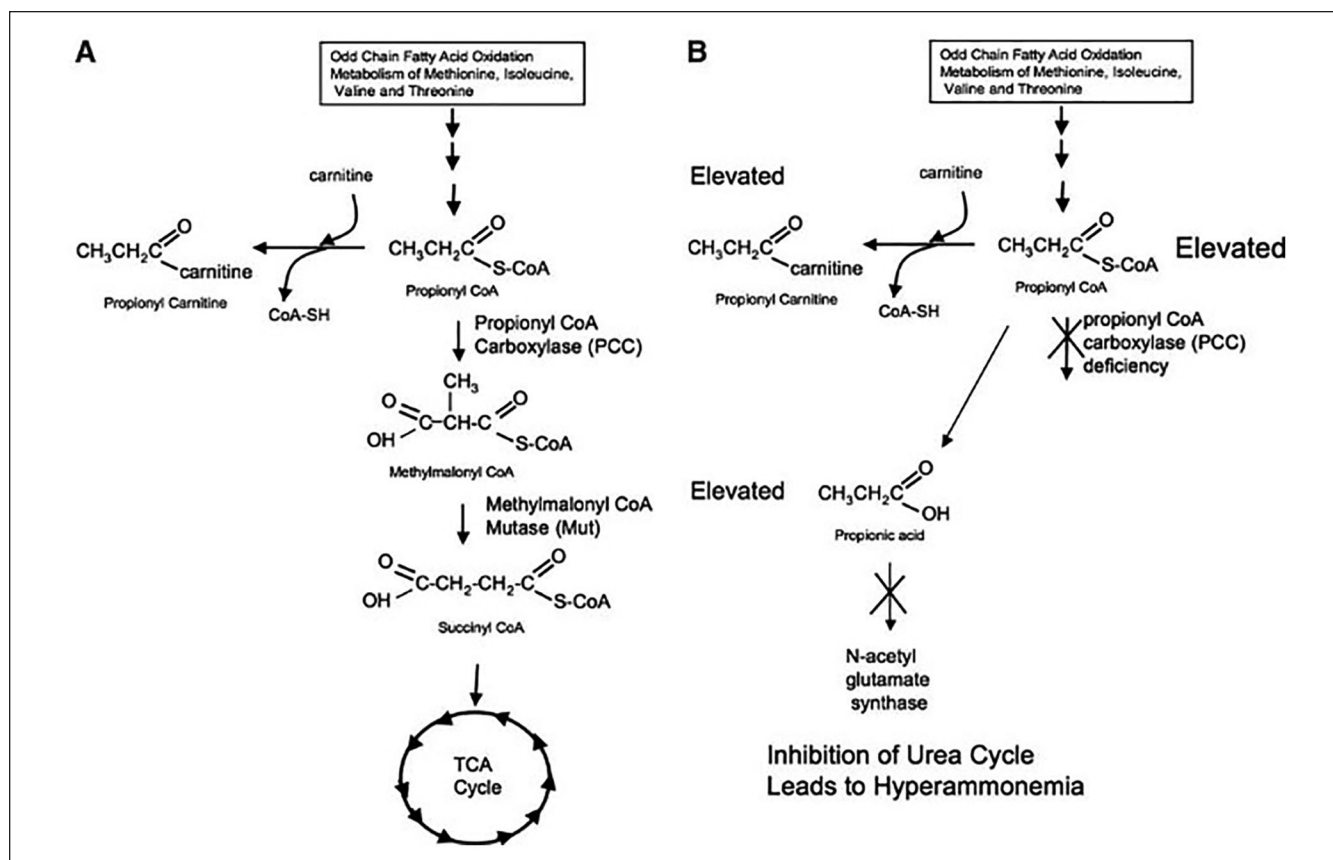
## Discussion

Propionic academia is an inborn error of metabolism characterized by accumulation of propionic acid due to deficiency of the enzyme propionyl-CoA carboxylase (Figure 1). Incidence of PA in the general population is 1:100 000 to 150 000 live births.<sup>1</sup> Newborn screening has allowed for increased identification of PA, but screening is not commonly performed and diagnosis usually occurs after the

onset of clinical symptoms early in life,<sup>5</sup> characterized by lethargy and vomiting. Laboratory analysis typically reveals a metabolic acidosis, hyperammonemia, and elevated urinary ketones,<sup>6</sup> metabolic derangements that are a result of states of increased catabolism. In our case, child had an initial presentation of lethargy and decreased oral intake at 3 days of age and had reportedly several episodes of hyperammonemia in his first 2 years of life.

Serum ammonia levels, urinary organic acids, and serum propionic acid are commonly followed.<sup>7</sup> Although there is poor correlation between exact laboratory values with risk of metabolic decompensations, it is best to monitor them regularly to establish trends in values and correlate with medical treatment. Ultimately disease progression is characterized by acute decompensations, triggered by acute illness or other stressors that promote increased catabolism, and long-term neurological and cardiac sequelae. The quantity and severity of metabolic decompensations may correlate with degree of neurologic damage.<sup>7</sup> This patient presented with developmental delay that was followed up with PT, OT, and speech therapy with slow improvement. It is recommended that these patients follow-up with pediatric cardiology for yearly evaluation with echocardiogram, electrocardiogram, and 24-hour holter.<sup>7</sup>

Chapman and colleagues discussed the recommendations for the management of acute decompensations for PA outlined during the 2011 PA consensus conference. The authors describe that as with any other medical emergencies, attention to basic life support is priority, and in some cases, patients may require interventions such as intubation for poor mental status. A key component outlined is avoiding prolonged periods of fasting, which leads to a catabolic state and potential decompensation. To prevent or reverse catabolic states, infusing 10% dextrose containing fluids and intralipids at 1.5 times maintenance is recommended. Additionally, patients may require removal of toxic metabolites and ammonia, which in severe cases can be achieved with hemodialysis.<sup>8</sup> Ammonia-scavenging agents such as sodium phenylacetate and sodium benzoate is dosed based on age and weight.<sup>9</sup> Carglumic acid (Carbaglu) is used to accelerate ammonia elimination by disinhibiting the urea cycle.<sup>8</sup> Correction of metabolic acidosis or electrolyte imbalances is also important. Levels of serum ammonia, acid/base status, and electrolytes should be followed at frequent intervals and treated accordingly. Carnitine supplementation is important as plasma levels of carnitine are inversely correlated with plasma levels of ammonia. It helps with the renal excretion of acylcarnitines. The recommended dose is 300 mg/kg/day.<sup>10</sup> Other medical treatment includes metronidazole, which as an intestinal bactericidal agent has been shown to decrease plasma and urine propionate metabolites.<sup>7</sup> In our case, the patient was admitted and preoperative laboratories were drawn, also dextrose infusion was started while fasting and the regular doses of L-carnitine continued as per the genetics team's recommendations until the time of incision.



**Figure 1.** Metabolic pathway for propionyl-CoA-carboxylase. A pathway: Normal patient. B pathway: Patient with propionic academia (PA).<sup>15</sup>

Despite strict adherence to medical management, many patients continue to have neurological and cardiac complications. OLT has been increasingly utilized in the management of PA, as it leads to the restoration of hepatic propionyl-CoA carboxylase.<sup>11</sup> It is shown to decrease frequency of metabolic decompensations and improve life expectancy.<sup>2</sup> Liver transplantation has been linked to an overall decrease in toxic metabolites, although complete elimination of metabolic derangements has been rarely reported.<sup>12</sup> The most significant benefit of early LT appears to be long-term neurological development and reduction in overall neurological sequelae.<sup>12</sup> Although removing the native liver is standard in OLT, Rajakumar and colleagues<sup>3</sup> report on 2 patients undergoing auxiliary partial OLT (APOLT), with the advantage that if the donor organ fails, this can be removed while preserving the native organ without a significant impact in the life of the recipient.

Perioperative management should include preoperative infusion of 10% dextrose solution, which should be continued intraoperatively to prevent episodes of catabolism. Use of insulin infusion should be considered to maintain blood glucose levels within normal range. Intraoperative metabolic control can be monitored using serum ammonia, amino acids, and urinary organic acids.<sup>2</sup> Postoperatively, patients

require PICU care, with average stay being reported in some studies as 6.5 days.<sup>2</sup>

Early extubation intraoperatively may help reduce the length of stay in the PICU, thus fast-tracking recovery.<sup>4</sup> Gurnaney and colleagues<sup>13</sup> conducted a retrospective cohort study examining early extubation in the OR following liver transplantation in pediatric patients. A total of 64 patients were included in the study, and 37 of the patients underwent early extubation. The study found that total time spent in the PICU and hospital overall was significantly lower in the early extubation group (mean 3.8 days [SD 2.1] vs mean 17.6 [SD 31.3] in delayed extubation group). Factors identified that may predict success of early extubation are amount of blood product transfused and lactate level at end of surgery.<sup>5</sup> However, in a different retrospective cohort study by Fullington and colleagues<sup>14</sup> did not find an association between these factors and success of early extubation. Instead, this study demonstrated the importance of clinician experience in determining on a case-by-case basis if immediate extubation will benefit the patient. Useful criteria for extubation after liver transplant have been described,<sup>4</sup> as follows: patient is awake and following verbal commands, adequate ventilation and oxygenation, hemodynamic stability, normothermia, and fully recovery from neuromuscular

blockade. In our case, based on the total blood loss, stable hemodynamics and blood gas values demonstrating adequate oxygenation and ventilation at the end of the procedure, we decided to extubate our patient in the OR and then transport to the PICU after making sure the patient would not decompensate. He was able to be weaned to room air by postoperative day 1, and was discharged from PICU on day 5.

Our take-home message is that liver transplantation is a promising treatment for patients with propionic acidemia as it helps reduce metabolic decompensations, reduces neurological sequelae, and prolongs life expectancy. An integral part of perioperative management is to reduce risk of catabolism by administering high calorie infusions, such as 10% dextrose and intralipids. Intraoperatively, markers of metabolic function such as serum ammonia and urinary ketones should be monitored at regular intervals. Last, early extubation may fast-track recovery of patients and reduce overall complications and time needed in intensive care.

### Author Contributions

Luis I. Rodriguez: Performed the anesthesia for the case, helped prepare write and review the manuscript. Erica J. Tainsh: Helped review the literature, prepared and wrote the manuscript. Eliane Vargas: Helped review the manuscript. Ana C. Mavarez: Performed the anesthesia for the case, helped review the literature, prepared and wrote the manuscript.

### Declaration of Conflicting Interests

The author(s) declared no potential conflicts of interest with respect to the research, authorship, and/or publication of this article.

### Funding

The author(s) received no financial support for the research, authorship, and/or publication of this article.

### Ethics Approval

Our institution does not require ethical approval for reporting individual cases or case series.

### Informed Consent

Written informed consent was obtained from a legally authorized representative for anonymized patient information to be published in this article.

### ORCID iD

Ana C. Mavarez  <https://orcid.org/0000-0003-4597-440X>

### References

1. Almasi T, Guey LT, Lukacs C, Csetneki K, Voko Z, Zelei T. Systematic literature review and meta-analysis on the epidemiology of propionic acidemia. *Orphanet J Rare Dis*. 2019;14:40.
2. Quintero J, Molera C, Juamperez J, et al. The role of liver transplantation in propionic acidemia. *Liver Transpl*. 2018;24:1736-1745.
3. Rajakumar A, Kaliamoorthy I, Reddy MS, Rela M. Anesthetic considerations for liver transplantation in propionic acidemia. *Indian J Anaesth*. 2016;60:50-54.
4. Ulukaya S, Arikian Ç, Aydogdu S, Ayanoglu HO, Tokat Y. Immediate tracheal extubation of pediatric liver transplant recipients in the operating room. *Pediatr Transplant*. 2003;7:381-384.
5. Citrelli K, McKiernan P, Vockley J, et al. Liver transplantation for propionic acidemia and methylmalonic acidemia: perioperative management and clinical outcomes. *Liver Transplant*. 2018;24:1260-1270.
6. Baumgartner MR, Hörster F, Dionisi-Vici C, et al. Proposed guidelines for the diagnosis and management of methylmalonic and propionic acidemia. *Orphanet J Rare Dis*. 2014;9:130.
7. Sutton VR, Chapman KA, Gropman AL, et al. Chronic management and health supervision of individuals with propionic acidemia. *Mol Genet Metab*. 2012;26-33.
8. Chapman KA, Gropman A, Macleod E, et al. Acute management of propionic acidemia. *Mol Genet Metab*. 2012;105:16-25.
9. Fraser JL, Venditti CP. Methylmalonic and propionic acidemias: clinical management update. *Curr Opin Pediatr*. 2016;28:682-693.
10. Yannicelli S. Nutritional management of patients with inherited disorders of organic acid metabolism. In: Acosta PB, ed. *Nutrition Management of Patients with Inherited Metabolic Disorders*. Jones & Bartlett; 2010:283-342.
11. Barshes NR, Vanatta JM, Patel AJ, et al. Evaluation and management of patients with propionic acidemia undergoing liver transplantation: a comprehensive review. *Pediatr Transplant*. 2006;10:773-781.
12. Nagao M, Tanaka T, Morri M, Wakai S, Horikawa R, Kasahara M. Improved neurologic prognosis for a patient with propionic acidemia who received early living donor liver transplantation. *Mol Genet Metab*. 2013;108:25-29.
13. Gurnaney HG, Cook-Sather SD, Shaked A, et al. Extubation in the operating room after pediatric liver transplant: a retrospective cohort study. *Paediatr Anaesth*. 2018;28:174-178.
14. Fullington NM, Cauley RP, Potanos KM, et al. Immediate extubation after pediatric liver transplantation: a single-center experience. *Liver Transpl*. 2015;21:57-62.
15. Hofherr S, Senac J, Chen C, Palmer D, Ng P, Barry M. Short-term rescue of neonatal lethality in a mouse model of propionic acidemia by gene therapy. *Hum Gene Ther*. 2008;20:169-180.