



Cystinosis

Galina Nesterova, MD¹ and William A Gahl, MD, PhD²

Created: March 22, 2001; Revised: December 7, 2017.

Summary

Clinical characteristics

Cystinosis comprises three allelic phenotypes:

- Nephropathic cystinosis in untreated children is characterized by renal Fanconi syndrome, poor growth, hypophosphatemic/calciopenic rickets, impaired glomerular function resulting in complete glomerular failure, and accumulation of cystine in almost all cells, leading to cellular dysfunction with tissue and organ impairment. The typical untreated child has short stature, rickets, and photophobia. Failure to thrive is generally noticed after approximately age six months; signs of renal tubular Fanconi syndrome (polyuria, polydipsia, dehydration, and acidosis) appear as early as age six months; corneal crystals can be present before age one year and are always present after age 16 months. Prior to the use of renal transplantation and cystine-depleting therapy, the life span in nephropathic cystinosis was no longer than ten years. With these interventions, affected individuals can survive at least into the mid-forties or fifties with satisfactory quality of life.
- Intermediate cystinosis is characterized by all the typical manifestations of nephropathic cystinosis, but onset is at a later age. Renal glomerular failure occurs in all untreated affected individuals, usually between ages 15 and 25 years.
- The non-nephropathic (ocular) form of cystinosis is characterized clinically only by photophobia resulting from corneal cystine crystal accumulation.

Diagnosis/testing

The diagnosis of cystinosis is established in a proband by one of the following:

- Identification of cystine crystals in the cornea on slit lamp examination
- Identification of elevated cystine concentration in polymorphonuclear leukocytes
- Demonstration of increased cystine content in cultured fibroblasts or in the placenta at the time of birth
- Identification of biallelic pathogenic variants in *CTNS* on molecular genetic testing

Author Affiliations: 1 Clinical Center, National Institutes of Health, Bethesda, Maryland; Email: nesterovag@mail.nih.gov.
2 Clinical Director, National Human Genome Research Institute, National Institutes of Health, Bethesda, Maryland; Email: bgahl@helix.nih.gov.

Management

Treatment of manifestations: Renal Fanconi syndrome is treated by replacement of tubular losses of electrolytes, bicarbonate, minerals, and other small molecular weight nutrients; children should have free access to water and bathroom privileges and supplementation with citrate to alkalinize the blood; phosphate replacement and vitamin D supplements are also used to prevent and treat rickets; skeletal deformities should be addressed early with the help of orthopedic specialists. Fluid and nutrient replacement is required during episodes of dehydration. For renal glomerular disease, oral cysteamine reduces cellular cystine; renal transplantation provides the ultimate treatment. Cysteamine eye drops relieve photophobia. Nutrition must be adequate to minimize failure to thrive in infants. Growth hormone replacement, L-thyroxine for hypothyroidism, insulin for diabetes mellitus, and testosterone for hypogonadism in males are all beneficial. Physical and speech therapy is helpful for the muscle deterioration and swallowing difficulties of older individuals.

Prevention of primary manifestations: Therapy with cystine-depleting agents begun as soon as the diagnosis is made or (if possible) shortly after birth will significantly slow the progression of glomerular damage; renal damage present at the time of diagnosis is irreversible. With optimal symptomatic and cystine-depleting therapy affected individuals grow at a normal rate but generally do not recover lost height unless human growth hormone is administered.

Prevention of secondary complications: Those who have undergone renal transplantation should be monitored for signs of immunodeficiency and infection; carnitine supplementation administered pre-transplant may improve muscle strength; treatment with proton pump inhibitors helps relieve cysteamine-induced gastric acid hypersecretion.

Surveillance: Evaluation by a nephrologist every three to six months depending on the severity of renal impairment; ophthalmologic evaluation every one to two years; assessment of bone mineralization throughout the disease course; fasting blood glucose concentration and testosterone concentration every two to three years (in males, starting before puberty); monitoring for late-onset complications by a multidisciplinary medical team.

Agents/circumstances to avoid: Dehydration; sun exposure if photophobia is present.

Evaluation of relatives at risk: Biochemical and/or molecular genetic testing (if the genetic status of the proband is known) allows for early diagnosis and treatment.

Genetic counseling

Cystinosis is inherited in an autosomal recessive manner. At conception, each sib of an affected individual has a 25% chance of being affected, a 50% chance of being an asymptomatic carrier, and a 25% chance of being unaffected and not a carrier. Carrier testing for at-risk relatives and prenatal diagnosis for pregnancies at increased risk are possible if both pathogenic variants have been identified in the family. For pregnancies at increased risk for nephropathic cystinosis, prenatal diagnosis is also possible biochemically, based on elevated cystine concentrations in both chorionic villi and amniocytes.

GeneReview Scope

Cystinosis: Included Phenotypes ¹

- Nephropathic cystinosis
- Intermediate cystinosis
- Non-nephropathic cystinosis

For synonyms and outdated names see Nomenclature.

1. For other genetic causes of these phenotypes see Differential Diagnosis.

Diagnosis

Cystinosis Standards of Care [Nesterova & Gahl 2012], developed and approved by international experts on cystinosis, is available [online](#).

Suggestive Findings

Nephropathic cystinosis should be suspected in infants and young children with the following clinical, laboratory, and radiographic features.

Clinical

- Failure to thrive and growth retardation from age six months
- Vomiting; feeding difficulties
- Severe polyuria, polydipsia, and dehydration
- Progressive rachitic skeletal changes; failure to walk at a normal age
- Tetany

Laboratory

- Hypochloremic metabolic acidosis
- Renal Fanconi syndrome: increased urinary excretion of electrolytes (sodium, potassium, bicarbonate), minerals (calcium, phosphate, magnesium), glucose, amino acids, tubular protein including β 2-microglobulin
- Elevated serum alkaline phosphatase, hypocalcemia, hypophosphatemia, hypokalemia

Radiographic

- Radiographic features of rickets including: bowing of the long bones in the lower extremities; metaphyses may be widened and epiphyses frayed or cupped; generalized osteopenia
- Renal ultrasound examination showing medullary nephrocalcinosis and/or increased echogenicity

Intermediate nephropathic cystinosis (juvenile/late onset) should be suspected in individuals exhibiting renal tubular Fanconi syndrome combined with progressive chronic glomerular insufficiency leading to end-stage renal disease (ESRD).

Ocular (non-nephropathic) cystinosis should be suspected in adults with photophobia and/or cystine crystals in the cornea on slit lamp examination (see Figure 1b).

Establishing the Diagnosis

The diagnosis of cystinosis is **established** in a proband by ONE of the following:

- Identification of cystine crystals in the cornea on slit lamp examination visible after age 12 months, and always present after age of 16 months (see Figure 1b)
- Identification of elevated cystine concentration in polymorphonuclear leukocytes
- Demonstration of increased cystine content in cultured fibroblasts or in the placenta at the time of birth
- Identification of biallelic pathogenic variants in *CTNS* on molecular genetic testing (see Table 1)

Elevated cystine concentration in polymorphonuclear leukocytes is best identified using mass spectrometry [Gahl et al 2001, Gahl et al 2002]:

- Individuals with nephropathic cystinosis generally have values of 3.0-23.0 nmol half-cystine/mg protein.
- Individuals with non-nephropathic cystinosis have values of 1.0-3.0 nmol half-cystine/mg protein.
- Heterozygotes have ≤ 1.0 nmol half-cystine/mg protein.

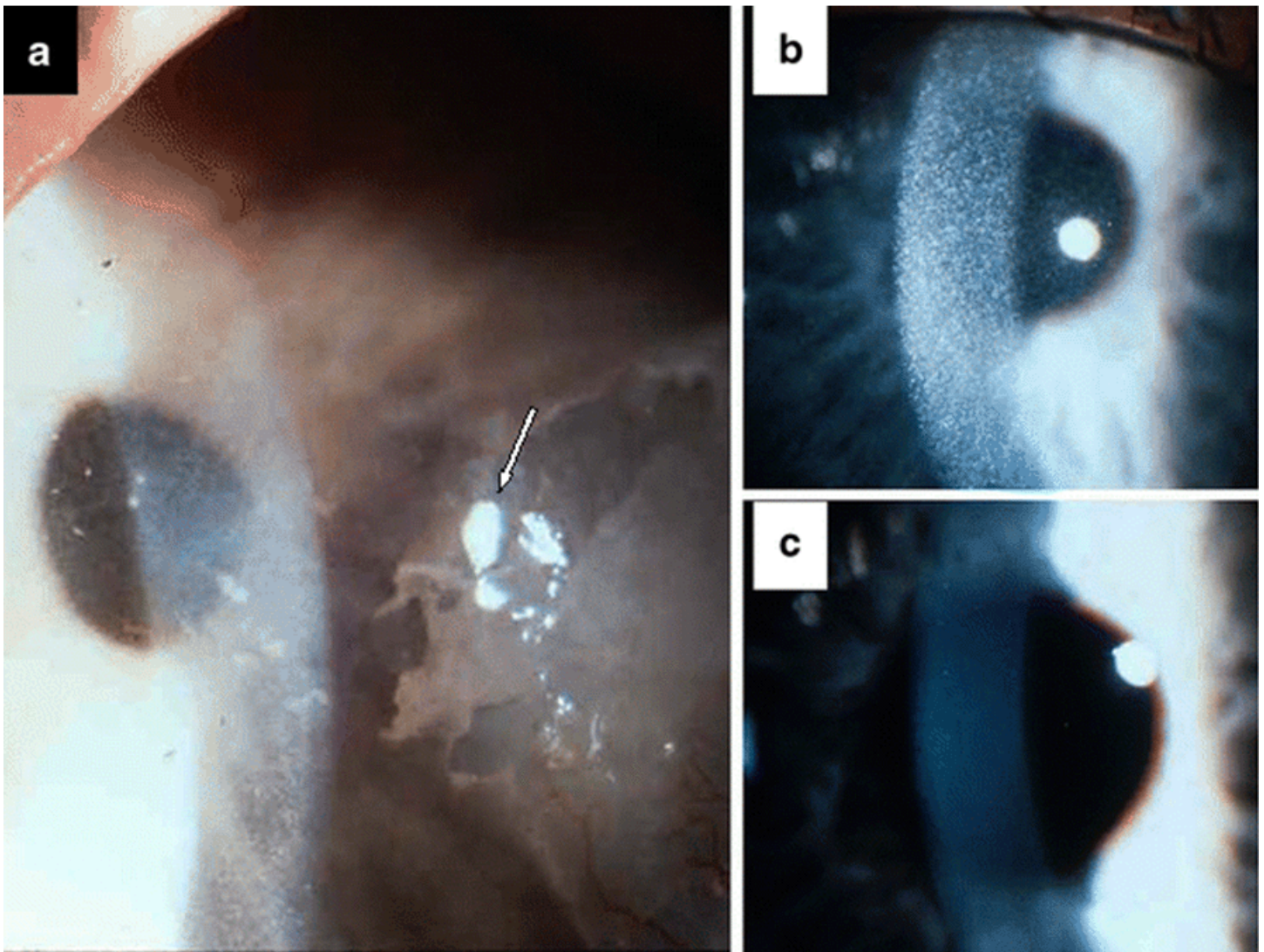


Figure 1. Findings on slit lamp examination of the cornea in cystinosis

a. Band keratopathy in a 33-year-old treated with cysteamine eye drops, which dissolved the cystine crystals, but not the calcified band

b. Corneal crystals in an untreated 43-month-old

c. The same child in panel b after 12 months of cysteamine eye drop therapy

Nesterova & Gahl [2008], with permission of Springer Science+Business Media

- Normal values are ≤ 0.2 nmol half-cystine/mg protein.

Note: (1) In preparing leukocytes for assay, care must be taken to avoid: (a) a significant number of lymphocytes, which store only fivefold normal amounts of cystine compared with 50-fold normal amounts in polymorphonuclear leukocytes; and (b) contamination with red blood cells, which contribute protein but not cystine to the calculated cystine value. Both interfering substances produce artifactually low leukocyte cystine levels. (2) Measurement by amino acid analysis (i.e., anion exchange chromatography) is less sensitive and can give spurious results if small amounts of leukocyte protein are available.

Other cystine measurements. Cystinosis can also be diagnosed by the demonstration of increased cystine content in cultured fibroblasts or in the placenta at the time of birth [Gahl et al 2001].

Molecular genetic testing

- **Single-gene testing.** For individuals of non-European ancestry, sequence analysis of *CTNS* is performed first and followed by gene-targeted deletion/duplication analysis if only one or no pathogenic variant is found.

Targeted analysis for the *CTNS*57-kb deletion in individuals of northern European ancestry may be performed first. Targeted analysis of *CTNS* pathogenic variants, optimized for the French-Canadian population, may be performed first.

- **A multigene panel** that includes *CTNS* and other genes of interest (see Differential Diagnosis) may also be considered. Note: (1) The genes included in the panel and the diagnostic sensitivity of the testing used for each gene vary by laboratory and are likely to change over time. (2) Some multigene panels may include genes not associated with the condition discussed in this *GeneReview*; thus, clinicians need to determine which multigene panel is most likely to identify the genetic cause of the condition at the most reasonable cost while limiting identification of variants of uncertain significance and pathogenic variants in genes that do not explain the underlying phenotype. (3) In some laboratories, panel options may include a custom laboratory-designed panel and/or custom phenotype-focused exome analysis that includes genes specified by the clinician. (4) Methods used in a panel may include sequence analysis, deletion/duplication analysis, and/or other non-sequencing-based tests.

For an introduction to multigene panels click [here](#). More detailed information for clinicians ordering genetic tests can be found [here](#).

- **More comprehensive genomic testing** (when available) including exome sequencing and genome sequencing may be considered if single-gene testing (and/or use of a multigene panel that includes *CTNS*) fails to confirm a diagnosis in an individual with features of cystinosis. Such testing may provide or suggest a diagnosis not previously considered (e.g., mutation of a different gene or genes that results in a similar clinical presentation).

For an introduction to comprehensive genomic testing click [here](#). More detailed information for clinicians ordering genomic testing can be found [here](#).

Table 1. Molecular Genetic Testing Used in Cystinosis

Gene ¹	Method	Proportion of Probands with Pathogenic Variants ² Detectable by Method
<i>CTNS</i>	Sequence analysis ³	56% ⁴
	Gene-targeted deletion/duplication analysis ⁵	44% ⁴

1. See Table A. Genes and Databases for chromosome locus and protein.

2. See Molecular Genetics for information on allelic variants detected in this gene.

3. Sequence analysis detects variants that are benign, likely benign, of uncertain significance, likely pathogenic, or pathogenic. Pathogenic variants may include small intragenic deletions/insertions and missense, nonsense, and splice site variants; typically, exon or whole-gene deletions/duplications are not detected. For issues to consider in interpretation of sequence analysis results, click [here](#).

4. Shotelersuk et al [1998], Attard et al [1999]

5. Gene-targeted deletion/duplication analysis detects intragenic deletions or duplications. Methods used may include quantitative PCR, long-range PCR, multiplex ligation-dependent probe amplification (MLPA), and a gene-targeted microarray designed to detect single-exon deletions or duplications.

Clinical Characteristics

Clinical Description

The three types of cystinosis – nephropathic (classic renal and systemic disease), intermediate (a late-onset variant of nephropathic cystinosis), and non-nephropathic (ocular) – are allelic disorders caused by pathogenic variants in *CTNS*.

Nephropathic and Intermediate (Nephropathic) Cystinosis

Nephropathic cystinosis. The clinical characteristics of untreated nephropathic cystinosis include those associated with failure to thrive, poor growth, renal tubular Fanconi syndrome, renal glomerular failure, and non-renal involvement of a variety of tissues and organ systems. With effective cystine-depleting therapy, cystinosis was transformed from a progressive, fatal renal disease to a treatable chronic multisystemic disease, with life span increasing from about ten years to 50 years or more [Nesterova & Gahl 2008].

- **Growth.** Infants with untreated nephropathic cystinosis are normal at birth. In untreated individuals, initially failure to thrive and later failure to grow are generally noticed between ages six and nine months. A high frequency of vomiting (usually in the morning), poor appetite, and feeding difficulties, combined with renal losses of nutrients, causes poor nutrition and severe failure to thrive. Typically, infants are at the third centile for height and weight at age one year [Gahl et al 2001, Gahl et al 2002]. Later, growth occurs at 60% of the normal rate. Bone age is usually delayed one to three years. Head circumference is normal for age.

With early and optimal symptomatic and cystine-depleting therapy, individuals grow at a normal rate. In the past, height often remained below the third centile and weight remained slightly above the third centile; however, recently, many affected infants and toddlers have height profiles following the 10th-25th centiles for age and falling in the range of mid-parental constitutional growth. Growth hormone administration improves height velocity in prepubertal children.

- **Renal tubular Fanconi syndrome.** Infants with untreated nephropathic cystinosis show signs of renal tubular Fanconi syndrome – i.e., generalized proximal tubular dysfunction – as early as age six months. The Fanconi syndrome involves failure of the renal tubules to reabsorb water, electrolytes, bicarbonate, phosphate, calcium, glucose, carnitine, amino acids, and tubular proteins. Individuals with untreated cystinosis have severe polyuria (2-6 L/day), polydipsia, dehydration, and hypochloremic metabolic acidosis, sometimes requiring hospitalization as a result of life-threatening hypovolemia, particularly during a gastrointestinal illness.

Hypophosphatemic/calcipenic rickets, characterized by high excretion of phosphate and calcium, elevated serum alkaline phosphatase, and bone deformities, make walking painful enough to delay ambulation. Nutritional deficiencies of vitamin D and calcium may accompany rickets, leading to seizures and tetany.

Severe hypokalemia can threaten cardiac conduction. Occasionally, hyponatremia and hypomagnesemia also occur.

Diligent treatment with replacement of renal losses is required for resolution of rickets, tetany, acidosis, and laboratory abnormalities. Cystine-depleting therapy begun just after birth when tubular damage is not complete can attenuate the renal tubular Fanconi syndrome [Kleta et al 2004a]. However, renal tubular damage present at the usual time of diagnosis (i.e., age ~1 year) is irreversible [Nesterova et al 2015].

- **Renal glomerular failure.** In the natural history of untreated nephropathic cystinosis, glomerular function gradually deteriorates, resulting in renal failure at approximately age ten years [Gahl et al 2001, Gahl et al 2002]. The serum creatinine concentration may not exceed 1.0 mg/dL until age five years, but

once it rises, it increases exponentially. Many affected individuals have significant proteinuria, sometimes in nephrotic ranges, along with granular casts and microhematuria.

Early treatment with cystine-depleting therapy (i.e., oral cysteamine) slows or stops the progression of glomerular damage and can delay or eliminate the need for renal transplantation [Kleta et al 2004a].

- **Non-renal involvement.** Without optimal therapy, cystine accumulation occurs in virtually all organs and tissues, including bone marrow, liver, intestine, muscle, brain, spleen, eye, thyroid, pancreas, and testes. Without therapy, several complications of cystinosis occur prior to renal transplantation:
 - Children with cystinosis have mildly altered craniofacial morphology, reduced airway dimensions, delayed dental development, and delayed eruption of permanent teeth [Bassim et al 2010].
 - Photophobia develops when the cornea becomes packed with crystals, generally at the end of the first decade of life.
 - Affected individuals typically develop hypothyroidism at the end of the first decade of life.
 - Sweating is impaired and affected individuals can suffer heat prostration [Gahl et al 2001, Gahl et al 2002].
 - Benign intracranial hypertension presents with headaches and papilledema [Dogulu et al 2004].
 - Puberty is generally delayed one to two years. Untreated males exhibit primary hypogonadism [Chik et al 1993].
 - A male with cystinosis is reported to have fathered a child through in vitro fertilization, with the sperm obtained by testicular biopsy [Veys et al 2018].
 - Several females with untreated cystinosis have delivered healthy children [Haase et al 2006].
 - It is currently not known whether diligent cysteamine treatment can prevent primary hypogonadism in males.
- **Late-onset abnormalities.** Well after renal transplantation (i.e., at age ~20-40 years), another set of complications can occur from the long-standing accumulation of cystine crystals in non-renal organs in individuals not treated with cysteamine [Servais et al 2008].
 - Increased cystine content in the muscles causes vacuolar myopathy in 60% of individuals [Gahl et al 2007]. Generalized myopathy leads to progressive muscle wasting and weakness (Figure 2a, 2c, 2d) [Charnas et al 1994]. Oral motor dysfunction causes swallowing and feeding difficulties [Trauner et al 2001, Sonies et al 2005]. Electromyography demonstrates a myopathic pattern.
 - Extrinsic chest muscle impairment causes extraparenchymal restriction of ventilation leading to pulmonary insufficiency with decreased values of FVC and FEV1 on routine pulmonary function tests [Anikster et al 2001].
 - Gastrointestinal findings can include reflux, dysmotility, esophagitis, gastric/duodenal ulcers, hepatomegaly with nodular regenerating hyperplasia of the liver with portal hypertension, exocrine pancreatic insufficiency [DiDomenico et al 2004, O'Brien et al 2006], inflammatory bowel disease, bowel perforation, and peritonitis [Gahl et al 2007].
 - Cardiovascular manifestations can include arteriopathy caused by the combination of vascular calcifications and obstructive atherosclerosis with hypercholesterolemia (Figure 2e) [Ueda et al 2006]; ESRD and renin-dependent hypertension; dilated cardiomyopathy; and aortic aneurysms. All of these factors contribute to cardiovascular morbidity and increase the risk for myocardial infarction and neurovascular incidents.
 - Metabolic bone disease develops as a result of direct deposition of cystine crystals in bone, mineral imbalance, and renal osteodystrophy prior to renal transplantation [Zimakas et al 2003].
 - Hypercoagulopathy and hypocoagulopathy occur as a result of renal failure and platelet aggregation dysfunction [Nesterova & Gahl 2008].

- CNS calcifications (Figure 2f), benign intracranial hypertension with non-absorptive hydrocephalus, and parenchymal deterioration of the central nervous system with cerebral atrophy lead to various degrees of encephalopathy [Gahl et al 2001, Gahl et al 2002]. Occasionally, cerebrovascular incidents with paresis or pseudobulbar palsy occur [Gahl et al 2007].
- **Intellectual abilities** are low-normal; affected children have mainly average school performance. They have impaired visual and spatial cognition with preserved language and intellectual function [Spilkin et al 2007]. Their distinctive behavioral and psychosocial difficulties stem from the chronic disease: ESRD, renal dialysis, prolonged hospitalizations, and treatment with multiple therapeutic agents, including steroids [Ballantyne & Trauner 2000, Delgado et al 2005].
- **Late ocular complications.** Crystal deposition in the anterior chamber, iris, ciliary body, choroid, fundus, and optic nerve manifests as [Tsilou et al 2007]:
 - Anterior segment problems. Crystals in the anterior lens surface, band keratopathy (Figure 1a), peripheral corneal neovascularization, and posterior synechiae;
 - Posterior segment problems. Pigmentary retinopathy with degeneration of the photoreceptors that contributes to the impaired visual function in the late stage of the disease [Tsilou et al 2002].

Intermediate cystinosis. All the early manifestations of untreated nephropathic cystinosis, including the renal tubular Fanconi syndrome, growth delay, photophobia, and glomerular failure, occur in individuals with untreated intermediate cystinosis, but at a later age, mostly during adolescence.

Histopathology. Electron microscopy of the glomeruli reveals fusion of foot processes, thickening of Bowman's membrane, and localization of cystine crystals in interstitial cells. Cystinotic glomeruli show focal glomerulosclerosis [Mahoney & Striker 2000].

Pathophysiology. The pathophysiology of renal tubular Fanconi syndrome is under investigation. Several mechanisms have been suggested:

- Inhibition of the Na-phosphate cotransporter resulting from cystine accumulation in the proximal tubular cells with depletion of intracellular ATP [Baum 1998, Kleta & Gahl 2002, Park et al 2002]
- Degeneration of the proximal tubules, which is well documented in nephropathic cystinosis [Mahoney & Striker 2000]
- Inappropriately increased apoptosis, leading to progressive cell death in proximal tubules resulting in atubular glomeruli and renal failure [Larsen et al 2010]
- Increased sensitivity of ATP-induced Ca^{2+} release in tubular cells [Ivanova et al 2015]
- Altered cell signaling resulting in impaired cell adhesion and enhanced cell motility [Ivanova et al 2016]

Non-Nephropathic Cystinosis

Individuals with untreated ocular cystinosis experience only photophobia.

Genotype-Phenotype Correlations

Some genotype-phenotype correlations can be made:

- Within the group of individuals with nephropathic cystinosis, truncating *CTNS* pathogenic variants, as well as the 57-kb deletion, result in severe, classic (early-onset or infantile type) disease [Shotelersuk et al 1998, Attard et al 1999].
- Individuals with apparent residual activity (i.e., lower levels of cystine accumulation in leukocytes) often have missense variants in *CTNS* [Attard et al 1999]. Individuals with intermediate cystinosis (i.e., nephropathic but late onset) or non-nephropathic cystinosis (i.e., corneal and bone marrow crystals but no renal involvement) have one severe *CTNS* pathogenic variant, typical for nephropathic cystinosis, and

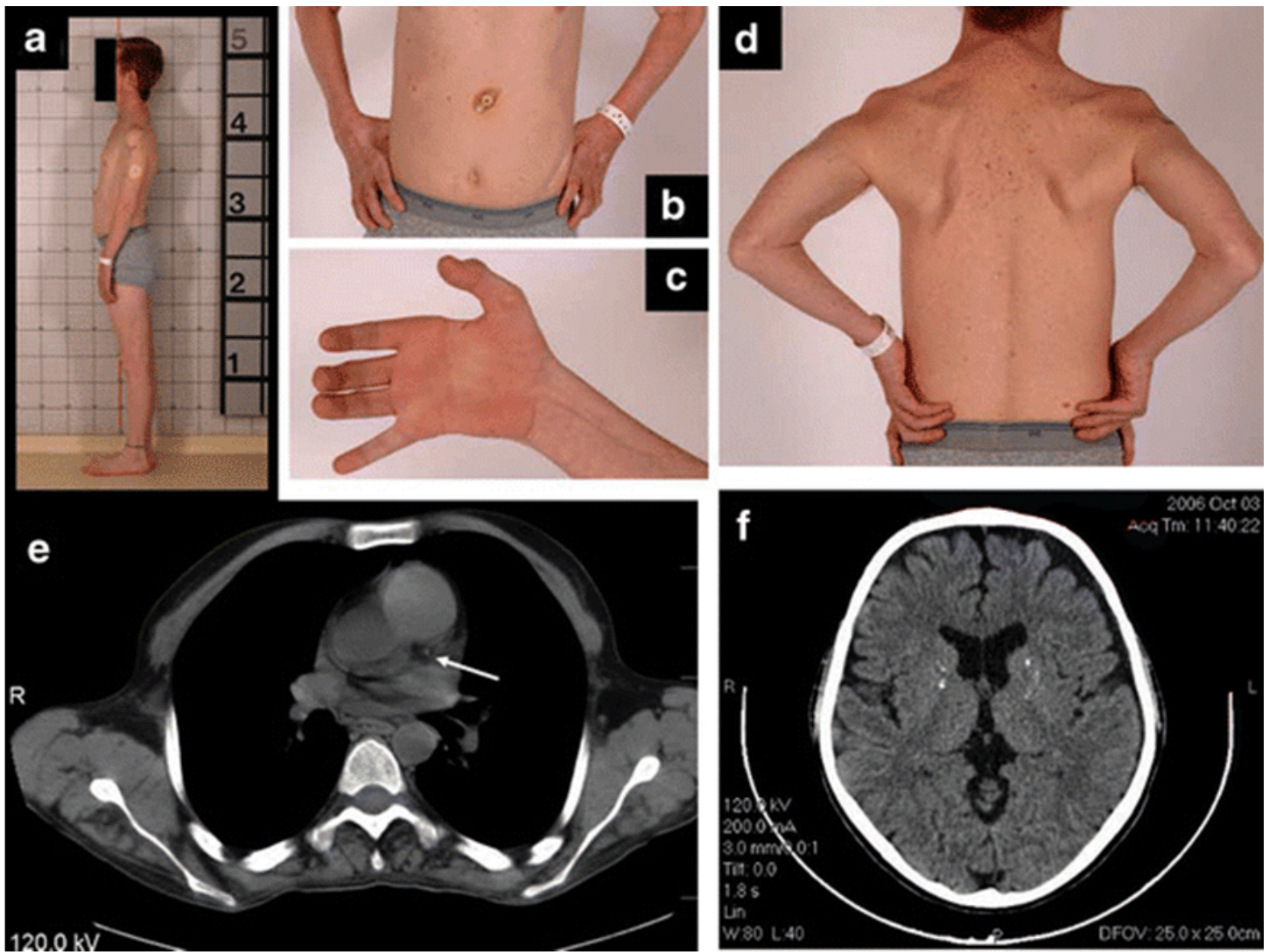


Figure 2. A man age 37 years with nephropathic cystinosis

- a. Thin habitus
 - b. Gastrostomy tube
 - c. Clawed hand with wasting of thenar and hypothenar eminences and interosseous muscles
 - d. Muscle wasting in upper trunk
 - e. CT scan of the chest showing calcification of the left coronary artery (arrow)
 - f. CT scan of the brain showing atrophy and calcifications of the basal ganglia
- Nesterova & Gahl [2008], with permission of Springer Science+Business Media

one mild pathogenic variant. The mild variants include p.Gly197Arg and c.853-3C>G [Anikster et al 1999]. The organ specificity in benign cystinosis may result from tissue-specific splicing factors.

- The pathogenic variant p.Ser139Phe may cause the juvenile phenotype [Macías-Vidal et al 2009].
- Deletions of *CTNS* and its flanking genes may lead to contiguous gene deletion syndromes with more complex phenotypes than those of classic cystinosis [Kalatzis & Antignac 2003]. For example, the 57-kb deletion on chromosome 17p13 extends into *TRPV1* causing dysregulation of *TRPV1* transcription in peripheral blood mononuclear cells [Freed et al 2011].
- Heterozygotes have 50% of transport capacity in their lysosomes [Thoene 1995, Gahl et al 2002].

- Loss of cystinosin may result in the unregulated activation of other transporters and pathways, including redox-based signaling or protein cysteinylolation [Bellomo et al 2010]. Other lysosomal functions may also be impaired in cystinosis [Wilmer et al 2010]. Studies of whole-genome expression profiles in peripheral blood samples from people with cystinosis identified modifier genes and pathways associated with nephropathic cystinosis; further investigation is needed to confirm the role of these genes in modulating the cystinosis phenotype [Sansanwal et al 2010].

Nomenclature

Nephropathic cystinosis is also referred to as infantile nephropathic type cystinosis.

Intermediate cystinosis is also referred to as adolescent (or juvenile) nephropathic type cystinosis.

The terms "adult cystinosis" and "benign cystinosis" should be replaced by "ocular cystinosis," "non-nephropathic cystinosis," or "ocular non-nephropathic cystinosis."

Prevalence

Cystinosis occurs with a frequency of approximately one in 100,000 to 200,000 and has been found worldwide in all ethnic groups. The frequency of cystinosis in Brittany has been given as one in 26,000 [Gahl et al 2001, Gahl et al 2002].

Cystinosis accounts for 5% of childhood renal failure [Middleton et al 2003].

Genetically Related (Allelic) Disorders

No phenotypes other than those discussed in this *GeneReview* are known to be associated with pathogenic variants in *CTNS*.

Differential Diagnosis

Renal tubular Fanconi syndrome. Untreated nephropathic cystinosis is the most common identifiable cause of renal tubular Fanconi syndrome in childhood. Other causes include:

- **Wilson disease** is a disorder of copper metabolism that can present with hepatic, neurologic, or psychiatric disturbances or a combination of these; onset ranges from age three to older than 50. Diagnosis depends in part on the detection of low serum copper and ceruloplasmin concentrations, Kayser-Fleischer rings in the cornea, and/or increased urinary copper excretion. Pathogenic variants in *ATP7B* are causative. Inheritance is autosomal recessive.
- **Lowe syndrome** (oculocerebrorenal syndrome) is found in males and involves the eyes (cataracts, glaucoma, decreased visual acuity), central nervous system (hypotonia, intellectual disability), and kidneys (Fanconi syndrome). Slowly progressive glomerulosclerosis and renal failure are often noted after age ten years. It is diagnosed by demonstrating reduced (<10% of normal) activity of phosphatidylinositol 4,5-bisphosphate 5-phosphatase in cultured skin fibroblasts. A pathogenic variant in *OCRL* is detectable in most males and carrier females. (Mutation of *OCRL1* can also cause **Dent disease**, which can present with findings typical for renal Fanconi syndrome.) Inheritance is X-linked.
- **Classic galactosemia** is a disorder of galactose metabolism that can result in feeding problems, failure to thrive, hepatocellular damage, bleeding, and sepsis in untreated infants. It is most often caused by deficient activity of the enzyme galactose-1-phosphate uridylyltransferase (*GALT*). The diagnosis of classic galactosemia is established by detection of elevated erythrocyte galactose-1-phosphate concentration, reduced erythrocyte *GALT* enzyme activity, and/or biallelic pathogenic variants in *GALT*. Inheritance is autosomal recessive.

- [Glycogen storage disease type I](#) presents mainly with hepatomegaly and hypoglycemia.
- [Tyrosinemia type I](#) presents with severe liver disease in infancy and shows abnormal tyrosine metabolites on organic acid analyses.
- Glucosuria associated with renal tubular Fanconi syndrome can result in misdiagnosis as diabetes mellitus.
- Polyuria often leads to a misdiagnosis of diabetes insipidus (see [Nephrogenic Diabetes Insipidus](#)).
- Electrolyte abnormalities can suggest Bartter syndrome.
- The rickets of cystinosis can falsely suggest vitamin D-deficient rickets.

Ocular (non-nephropathic) cystinosis. Multiple myeloma can cause photophobia and corneal crystals similar to those in ocular cystinosis [Kleta et al 2004b].

Management

Clinical practice guidelines for the treatment of individuals with cystinosis, developed and approved by international experts on cystinosis, have been published. See [Cystinosis Standards of Care](#) [Nesterova & Gahl 2012].

Evaluations Following Initial Diagnosis

To establish the extent of disease and needs in an individual diagnosed with cystinosis, the following evaluations are recommended.

In individuals who are initially diagnosed at any age:

- Height and weight, plotted on age-appropriate growth charts
- Renal tubular and glomerular function, especially serum concentrations of creatinine, phosphate, bicarbonate, and potassium; and urine concentrations of creatinine, phosphate, bicarbonate, potassium, glucose, and protein. Quantitative measurement of urine amino acid loss helps to identify the severity of renal Fanconi syndrome [Charnas et al 1991].
- Glomerular filtration rate (GFR) or creatinine clearance test
- Thyroid function studies
- Lipid panel
- Renal ultrasound examination for evaluation of nephrocalcinosis
- Ophthalmologic evaluation, including slit lamp examination of the cornea to assess corneal involvement, ERG to assess retinal involvement, and fundoscopic examination for possible intracranial hypertension
- Consultation with a clinical geneticist and/or genetic counselor

In individuals who are initially diagnosed at an older age:

- In pre- and postpubertal males, measurement of serum concentration of testosterone, FSH, and LH
- Glucose tolerance test to assess for diabetes mellitus if symptoms are present
- Baseline ophthalmology evaluation, including a fundoscopic examination
- Evaluation of the extent of metabolic bone disease causing skeletal deformities by performing skeletal radiographs and DEXA scan
- Consultation with a clinical geneticist and/or genetic counselor

Treatment of Manifestations

It is recommended that a multidisciplinary team that includes nephrologists, metabolic disease specialists, ophthalmologists, neurologists, gastroenterologists, nutritionists, and psychologists manage individuals with cystinosis.

Renal Fanconi syndrome

- Replacement of tubular losses of electrolytes, bicarbonate, minerals, and other small molecular weight nutrients
- For children, free access to water and bathroom privileges and supplementation with citrate to alkalinize the blood
- Phosphate replacement to prevent and treat rickets; vitamin D supplementation to assist the gastrointestinal absorption of phosphate and calcium
- Early treatment of skeletal deformities with the help of orthopedic specialists
- Careful attention to fluid and nutrient replacement is required during episodes of dehydration. (Obligatory urinary losses amount to 2-6 L electrolyte-rich water per day.)

Renal glomerular disease

- Reduction of cellular cystine concentration through treatment with the cystine-depleting agent cysteamine (see Prevention of Primary Manifestations).
- Renal transplantation. Renal replacement is usually indicated when the creatinine clearance falls below 20 mL/min/1.73 m² and azotemia and hypertension rapidly progress. The time frame for appropriate renal replacement is the point at which the reciprocal serum creatinine value plotted against age reaches approximately 0.1. Symptoms often determine the exact time of transplantation.

Ophthalmologic problems are treated symptomatically and with cystine-depleting agents:

- The photophobia, resulting from corneal crystal accumulation, can be ameliorated by sun avoidance, dark glasses, and lubrication with over-the-counter eye drops (see Prevention of Primary Manifestations).
- Corneal transplantation is very rarely required for intractable pain resulting from recurrent corneal ulcerations.
- Retinal involvement is irreversible.

Growth for children with cystinosis requires good nutrition, adequate phosphate supplementation, and robust intracellular cystine depletion (see Prevention of Primary Manifestations):

- Nutrition must be adequate for growth.
- Growth hormone therapy has proven beneficial for children with cystinosis in providing catch-up growth and bringing them into the normal centiles for height [Gahl et al 2001, Wühl et al 2001, Gahl et al 2002].
- Early and diligent treatment with supplements and oral cysteamine can obviate the need for growth hormone [Kleta et al 2004a].

Other

- Oral L-thyroxine replacement for hypothyroidism
- Insulin for diabetes mellitus
- Testosterone to induce secondary sexual characteristics in males with primary hypogonadism
- Specific exercises for the muscle deterioration and swallowing difficulties of older individuals with cystinosis. Hand tendon transfer has been partially successful in improving strength.
- Speech therapy and physical therapy
- Standard treatment for benign intracranial hypertension. Other central nervous system complications are irreversible.
- Feeding via gastrostomy for those with dysphagia, poor nutrition, and risk of aspiration (Figure 2b)

Prevention of Primary Manifestations

Cystine depletion therapy with cysteamine bitartrate (Cystagon®) has revolutionized the management and prognosis of people with nephropathic cystinosis. Cysteamine is now the worldwide treatment of choice for cystinosis. This free thiol can deplete cystinotic cells of more than 90% of their cystine content [Kleta & Gahl 2004]. Wilmer et al [2011] found that cysteamine also increased intracellular glutathione levels and restored the glutathione redox status of cystinotic cells.

Cysteamine therapy should be considered for all affected individuals, regardless of age and transplantation status [Gahl et al 2007]. With early, diligent treatment many individuals with cystinosis have survived into their twenties without the need for renal transplantation [Gahl et al 2002].

- Regular and diligent cysteamine therapy prevents or delays end-stage renal disease (ESRD) [Markello et al 1993] and hypothyroidism, enhances growth, and depletes muscle parenchyma of cystine [Gahl et al 2002].
- It is critical to initiate cysteamine therapy immediately after diagnosis to allow for kidney growth and acquisition, rather than loss, of renal function [Kleta et al 2004a].
- Cystagon® is taken orally every six hours at 60 to 90 mg of free base per kg per day (1.3 to 1.95 g/m²/day). The recommended adult dose is 500 mg free base every six hours; however, for both children and adults, the dose is titrated to reduce, if possible, leukocyte cystine concentration (measured 5-6 hours after a dose) to below 1.0 nmol half-cystine/mg protein [Belldina et al 2003, Kleta & Gahl 2004, Kleta 2006].
- Procysbi® (cysteamine bitartrate) is a delayed-release capsule intended for affected individuals age six years and older. Procysbi® is taken every 12 hours. Blood testing showed Procysbi® was noninferior to Cystagon® in controlling cystine levels [Langman et al 2012].
- Side effects of cysteamine treatment include nausea and vomiting, in part because of its unpleasant odor and taste [Schneider 2004]. Cysteamine increases gastrin synthesis and gastric acid production. Omeprazole may be of benefit for oral cysteamine treatment [Dohil et al 2003].
- With long-term cystine-depleting therapy most late complications of cystinosis can be avoided.
- Despite diligent oral cysteamine therapy, cysteamine hydrochloride eye drops or CYSTARAN™ (cysteamine ophthalmic solution) 0.44% are required to achieve sufficient tissue concentration to dissolve corneal crystals [Gahl et al 2000]. Cysteamine eye drops are given ten to 12 times per day as a 0.55% solution with benzalkonium chloride 0.01% as a preservative [Tsilou et al 2007]. With good compliance photophobia is relieved within weeks (Figure 1b, 1c) [Kaiser-Kupfer et al 1987, Gahl et al 2000]. Systemic cysteamine treatment ameliorates or postpones retinal deterioration [Tsilou et al 2006].

Prevention of Secondary Complications

Affected individuals who have undergone a renal transplantation should be monitored for the signs of immunodeficiency and infection.

Carnitine supplementation may improve muscle strength in pre-transplant individuals.

Treatment with proton pump inhibitors, such as omeprazole, relieves cysteamine-induced gastric acid hypersecretion and improves gastrointestinal symptoms [Osefo et al 2009].

Surveillance

Clinical and laboratory examinations should be performed in individuals with nephropathic cystinosis according to disease severity and may include renal, endocrine, ophthalmologic, neurologic, and cardiac examinations [Kleta et al 2005]:

- Evaluation by a nephrologist every three to six months depending on the severity of renal impairment

- Renal function tests, electrolytes, and thyroid function tests at least every three to six months in those who are stable
- Serum concentration of calcium, phosphate, alkaline phosphatase, and intact parathyroid hormone; plain bone radiographs as well as DEXA scans to detect osteopenia and bone fragility predisposing to fractures, starting as soon as diagnosis is made and continued throughout the course of the disease
- Ophthalmologic evaluation with fundoscopic examination to screen for increased intracranial pressure every one to two years for those being treated appropriately
- Fasting blood glucose concentration throughout the course of the disease and testosterone concentration (in males) every two to three years, starting before puberty
- In advanced disease (i.e., poorly treated adults) and in late stages of disease, perform every two to three years:
 - Chest CT for detection of coronary and other vascular calcification
 - ECG
 - Brain CT or MRI for evaluation of cerebral atrophy or calcifications
 - Evaluation for the presence of progressive muscle weakness and swallowing difficulties using electromyography (EMG), oral sensorimotor examination, and modified barium swallowing studies with videofluoroscopy
 - Pulmonary function tests
 - Neurologic and neurocognitive evaluations including visual-motor integration, visual memory, planning, sustained attention, and motor speed beginning at age seven to eight years [Besouw et al 2010a]

Agents/Circumstances to Avoid

Avoid the following:

- Dehydration, which compromises remaining renal function
- Sun exposure, which can exacerbate photophobia

Evaluation of Relatives at Risk

It is appropriate to evaluate relatives at risk (e.g., newborn sibs of a proband) in order to identify as early as possible those who would benefit from early treatment to prevent life-threatening complications of cystinosis.

Evaluations can include:

- Molecular genetic testing if the pathogenic variants in the family are known;
- Biochemical testing if the pathogenic variants in the family are not known.

See Genetic Counseling for issues related to testing of at-risk relatives for genetic counseling purposes.

Pregnancy Management

Pregnancies in women with cystinosis are at increased risk for premature delivery and must be monitored closely [Ramappa & Pyatt 2010]. For women who are post-transplantation, the abdominal renal allograft creates mechanical issues. For women who have not undergone transplantation, fluid and electrolyte status require careful management.

Therapies Under Investigation

Bone marrow-derived stem cell transplantation in mice improved chronic kidney disease [Yeagy et al 2011].

Search [ClinicalTrials.gov](https://clinicaltrials.gov) in the US and [EU Clinical Trials Register](https://clinicaltrialsregister.eu) in Europe for access to information on clinical studies for a wide range of diseases and conditions.

Other

Development of a newborn screening test for cystinosis will potentially allow broader therapeutic success [Nesterova & Gahl 2008]. Two methods have been proposed: tandem mass spectrometry for the determination of derivative seven-carbon (C7) sugars in dried blood spots (DBS), which detects homozygosity for the *CTNS* 57-kb deletion, and molecular genetic testing for the most common *CTNS* pathogenic variants [Wamelink et al 2011].

Therapies proven to be ineffective include dietary restriction of sulfur-containing amino acids, supplementation with ascorbic acid, and the use of dithiothreitol.

Genetic Counseling

Genetic counseling is the process of providing individuals and families with information on the nature, inheritance, and implications of genetic disorders to help them make informed medical and personal decisions. The following section deals with genetic risk assessment and the use of family history and genetic testing to clarify genetic status for family members. This section is not meant to address all personal, cultural, or ethical issues that individuals may face or to substitute for consultation with a genetics professional. —ED.

Mode of Inheritance

All forms of cystinosis are inherited in an autosomal recessive manner.

Risk to Family Members

Parents of a proband

- The parents of an affected child are obligate heterozygotes (i.e., carriers of one *CTNS* pathogenic variant).
- Heterozygotes (carriers) are asymptomatic and are not at risk of developing the disorder.

Sibs of a proband

- At conception, each sib of an affected individual has a 25% chance of being affected, a 50% chance of being an asymptomatic carrier, and a 25% chance of being unaffected and not a carrier.
- Heterozygotes (carriers) are asymptomatic and are not at risk of developing the disorder.

Offspring of a proband

- The offspring of an individual with cystinosis are obligate heterozygotes (carriers) for a *CTNS* pathogenic variant.
- Rarely, families with two-generation involvement (sometimes called "pseudodominance") have been identified; two-generation involvement results from an affected individual having children with a partner who is heterozygous (i.e., a carrier) for a *CTNS* pathogenic variant.

Other family members. Each sib of the proband's parents is at a 50% risk of being a carrier of a *CTNS* pathogenic variant.

Carrier (Heterozygote) Detection

Biochemical testing. Carrier testing can be performed biochemically; it requires freshly prepared leukocytes and appropriate controls.

Molecular genetic testing. Carrier testing for at-risk family members is possible if the pathogenic variants in the family are known.

Related Genetic Counseling Issues

See Management, Evaluation of Relatives at Risk for information on evaluating at-risk relatives for the purpose of early diagnosis and treatment.

Family planning

- The optimal time for determination of genetic risk, clarification of carrier status, and discussion of the availability of prenatal testing is before pregnancy.
- It is appropriate to offer genetic counseling (including discussion of potential risks to offspring and reproductive options) to young adults who are affected, are carriers, or are at risk of being carriers.
- Women with cystinosis have had successful pregnancies resulting in healthy newborns; however, the potential teratogenic effects of cysteamine on fetuses have not been studied in humans.
- Very limited data on fertility in males with cystinosis exist; several individuals have been reported with aspermia. However, one individual had sufficient spermatogenesis in a testicular biopsy to father a child through in vitro fertilization [Veys et al 2018]. Cryopreservation of sperm could be considered in affected males [Besouw et al 2010b].

DNA banking is the storage of DNA (typically extracted from white blood cells) for possible future use. Because it is likely that testing methodology and our understanding of genes, allelic variants, and diseases will improve in the future, consideration should be given to banking DNA of affected individuals.

Prenatal Testing and Preimplantation Genetic Diagnosis

Biochemical testing. For pregnancies at risk for nephropathic cystinosis, prenatal diagnosis is possible biochemically, based on elevated cystine concentrations in either chorionic villi or amniocytes obtained by amniocentesis [Gahl et al 2001].

Molecular genetic testing. Once the *CTNS* pathogenic variants have been identified in an affected family member, prenatal testing for a pregnancy at increased risk and preimplantation genetic diagnosis for cystinosis are possible.

Differences in perspective may exist among medical professionals and within families regarding the use of prenatal testing, particularly if the testing is being considered for the purpose of pregnancy termination rather than early diagnosis. While most centers would consider decisions regarding prenatal testing to be the choice of the parents, discussion of these issues is appropriate.

Resources

GeneReviews staff has selected the following disease-specific and/or umbrella support organizations and/or registries for the benefit of individuals with this disorder and their families. GeneReviews is not responsible for the information provided by other organizations. For information on selection criteria, click [here](#).

- **Cystinosis Foundation**

Links to international cystinosis consumer groups can be found on The Cystinosis Foundation homepage.

Phone: 888-631-1588 (toll-free); 925-631-1588

www.cystinosis.com

- **Cystinosis Ireland**

Ireland

Email: mail@cystinosis.ie

www.cystinosis.ie

- **Cystinosis Research Foundation Natalie's Wish**

18802 Bardeen Avenue

Irvine CA 92612

www.cystinosisresearch.org

- **Cystinosis Research Network (CRN)**

302 Whytegate Court

Lake Forest IL 60045

Phone: 866-276-3669 (toll-free); 847-735-0471

Fax: 847-235-2773

Email: info@cystinosis.org

www.cystinosis.org

- **Metabolic Support UK**

5 Hilliards Court, Sandpiper Way

Chester Business Park

Chester CH4 9QP

United Kingdom

Phone: 0845 241 2173

Email: contact@metabolicsupportuk.org

www.metabolicsupportuk.org

Molecular Genetics

Information in the Molecular Genetics and OMIM tables may differ from that elsewhere in the GeneReview: tables may contain more recent information. —ED.

Table A. Cystinosis: Genes and Databases

Gene	Chromosome Locus	Protein	Locus-Specific Databases	HGMD	ClinVar
CTNS	17p13.2	Cystinosin	CTNS database	CTNS	CTNS

Data are compiled from the following standard references: gene from [HGNC](#); chromosome locus from [OMIM](#); protein from [UniProt](#). For a description of databases (Locus Specific, HGMD, ClinVar) to which links are provided, click [here](#).

Table B. OMIM Entries for Cystinosis ([View All in OMIM](#))

219750	CYSTINOSIS, ADULT NONNEPHROPATHIC
219800	CYSTINOSIS, NEPHROPATHIC; CTNS
219900	CYSTINOSIS, LATE-ONSET JUVENILE OR ADOLESCENT NEPHROPATHIC TYPE
606272	CYSTINOSIN; CTNS

Gene structure. *CTNS* is 26 kb in length and has 12 exons with a coding region of 1,104 bp [Town et al 1998]. For a detailed summary of gene and protein information, see Table A, **Gene**.

Pathogenic variants. At least 128 different pathogenic variants including promoter variants in *CTNS* have been reported in HGMD; they are found in different combinations in individuals with cystinosis [Shotelersuk et al 1998, Town et al 1998, Attard et al 1999, McGowan-Jordan et al 1999, Thoene et al 1999, Anikster et al 2000, Kleta et al 2001, Phornphutkul et al 2001, Kalatzis et al 2002, Kiehntopf et al 2002, Mason et al 2003]. Pathogenic variant types include missense, nonsense, and splice site variants, deletions, and insertions leading to downstream stop codons or abolition of splice sites [Kiehntopf et al 2002]. The missense variants are usually present within transmembrane regions [Anikster et al 1999]. There are no mutational hot spots.

By far the most common pathogenic variant (50% of affected individuals) is the 57-kb deletion involving exons 1-9 and part of exon 10; this variant apparently represents a founder effect [Shotelersuk et al 1998]. Another relatively common pathogenic variant is p.Trp138Ter. A higher incidence of infantile cystinosis (1:26,000) was reported in the French province of Brittany. The splice site variant c.898_900+24del27 segregates in certain unrelated families [Kalatzis et al 2002]. (For more information, see Table A.)

Table 2. *CTNS* Pathogenic Variants Discussed in This *GeneReview*

DNA Nucleotide Change	Predicted Protein Change	Reference Sequences
g.36,254_93,510del (57-kb del) ¹	--	AF168787
c.18_21del4	p.Thr7PhefsTer7	NM_004937.2 NP_004928.2
c.198_218del (198del21bp or 537del21) ²	p.Ile67_Pro73del	
c.382C>T	p.Gln128Ter	
c.397A>T	p.Ile133Pro	
c.414G>A	p.Trp138Ter	
c.416C>T	p.Ser139Phe	
c.473T>C	p.Leu158Pro	
c.544T>C	p.Trp182Arg	
c.589G>A	p.Gly197Arg	
c.611_613del3	p.Asp205del	
c.853-3C>G	-- ³	
c.898_900+24del27	--	
c.922G>A	p.Gly308Arg	

Note on variant classification: Variants listed in the table have been provided by the authors. *GeneReviews* staff have not independently verified the classification of variants.

Note on nomenclature: *GeneReviews* follows the standard naming conventions of the Human Genome Variation Society (varnomen.hgvs.org). See [Quick Reference](#) for an explanation of nomenclature.

1. Touchman et al [2000]

2. Variant designation that does not conform to current naming conventions

3. Anikster et al [2000]

Normal gene product. Cystinosin, the protein product of *CTNS*, is a 367-amino acid peptide with seven transmembrane and two lysosomal targeting motifs, a 128-amino acid N-terminal region bearing seven potential N-glycosylation sites, and a ten-amino acid cytosolic C-terminal tail [Town et al 1998, Kalatzis & Antignac 2002, Kalatzis & Antignac 2003]. Cystinosin is expressed in the cells of virtually all tissues. Cystinosin

transports the disulfide amino acid cystine out of the lysosome and into the cytoplasm [Gahl et al 2002, Kleta & Gahl 2002]. Cystinosis is highly conserved between man and mouse [Cherqui et al 2002].

Abnormal gene product. The 57-kb deletion allele produces no *CTNS* mRNA, while most other alleles produce some residual mRNA [Shotelersuk et al 1998]. The mutated alleles of *CTNS* are predicted to produce truncated cystinosis in the case of severely affected individuals and to produce cystinosis that retains some residual function in the case of mildly affected individuals.

References

Published Guidelines/Consensus Statements

- Emma F, Nesterova G, Langman C, Labbé A, Cherqui S, Goodyer P, Janssen MC, Greco M, Topaloglu R, Elenberg E, Dohil R, Trauner D, Antignac C, Cochat P, Kaskel F, Servais A, Wühl E, Niaudet P, Van't Hoff W, Gahl W, Levchenko E. Nephropathic cystinosis: an international consensus document. Available [online](#). 2014. Accessed 6-19-19.
- Nesterova G, Gahl WA. Infantile nephropathic cystinosis standards of care – a reference for people with infantile nephropathic cystinosis, their families, and medical team. Cystinosis Research Network. Available [online](#). 2012. Accessed 6-19-19.

Literature Cited

- Anikster Y, Lacbawan F, Brantly M, Gochuico BL, Avila NA, Travis W, Gahl WA. Pulmonary dysfunction in adults with nephropathic cystinosis. *Chest*. 2001;119:394–401. PubMed PMID: 11171714.
- Anikster Y, Lucero C, Guo J, Huizing M, Shotelersuk V, Bernardini I, McDowell G, Iwata F, Kaiser-Kupfer MI, Jaffe R, Thoene J, Schneider JA, Gahl WA. Ocular nonnephropathic cystinosis: clinical, biochemical, and molecular correlations. *Pediatr Res*. 2000;47:17–23. PubMed PMID: 10625078.
- Anikster Y, Shotelersuk V, Gahl WA. *CTNS* mutations in patients with cystinosis. *Hum Mutat*. 1999;14:454–8. PubMed PMID: 10571941.
- Attard M, Jean G, Forestier L, Cherqui S, van't Hoff W, Broyer M, Antignac C, Town M. Severity of phenotype in cystinosis varies with mutations in the *CTNS* gene: predicted effect on the model of cystinosis. *Hum Mol Genet*. 1999;8:2507–14. PubMed PMID: 10556299.
- Ballantyne AO, Trauner DA. Neurobehavioral consequences of a genetic metabolic disorder: visual processing deficits in infantile nephropathic cystinosis. *Neuropsychiatry Neuropsychol Behav Neurol*. 2000;13:254–63. PubMed PMID: 11186161.
- Bassim CW, Gautam P, Domingo DL, Balog JZ, Guadagnini JP, Gahl WA, Hart TC. Craniofacial and dental findings in cystinosis. *Oral Dis*. 2010;16:488–95. PubMed PMID: 20233313.
- Baum M. The Fanconi syndrome of cystinosis: insights into the pathophysiology. *Pediatr Nephrol*. 1998;12:492–7. PubMed PMID: 9745876.
- Belldina EB, Huang MY, Schneider JA, Brundage RC, Tracy TS. Steady-state pharmacokinetics and pharmacodynamics of cysteamine bitartrate in paediatric nephropathic cystinosis patients. *Br J Clin Pharmacol*. 2003;56:520–5. PubMed PMID: 14651726.
- Bellomo F, Corallini S, Pastore A, Palma A, Laurenzi C, Emma F, Taranta A. Modulation of *CTNS* gene expression by intracellular thiols. *Free Radic Biol Med*. 2010;48:865–72. PubMed PMID: 20079424.
- Besouw MT, Hulstijn-Dirkmaat GM, van der Rijken RE, Cornelissen EA, van Dael CM, Vande Walle J, Lilien MR, Levchenko EN. Neurocognitive functioning in school-aged cystinosis patients. *J Inherit Metab Dis*. 2010a;33:787–93. PubMed PMID: 20814825.

- Besouw MT, Kremer JA, Janssen MC, Levtchenko EN. Fertility status in male cystinosis patients treated with cysteamine. *Fertil Steril*. 2010b;93:1880–3. PubMed PMID: 19217094.
- Charnas LR, Bernardini I, Rader D, Hoeg JM, Gahl WA. Clinical and laboratory findings in the oculocerebrorenal syndrome of Lowe, with special reference to growth and renal function. *N Engl J Med*. 1991;324:1318–25. PubMed PMID: 2017228.
- Charnas LR, Luciano CA, Dalakas M, Gilliatt RW, Bernardini I, Ishak K, Cwik VA, Fraker D, Brushart TA, Gahl WA. Distal vacuolar myopathy in nephropathic cystinosis. *Ann Neurol*. 1994;35:181–8. PubMed PMID: 8109899.
- Cherqui S, Sevin C, Hamard G, Kalatzis V, Sich M, Pequignot MO, Gogat K, Abitbol M, Broyer M, Gubler MC, Antignac C. Intralysosomal cystine accumulation in mice lacking cystinosin, the protein defective in cystinosis. *Mol Cell Biol*. 2002;22:7622–32. PubMed PMID: 12370309.
- Chik CL, Friedman A, Merriam GR, Gahl WA. Pituitary-testicular function in nephropathic cystinosis. *Ann Intern Med*. 1993;119:568–75. PubMed PMID: 8363167.
- Delgado G, Schatz A, Nichols S, Appelbaum M, Trauner D. Behavioral profiles of children with infantile nephropathic cystinosis. *Dev Med Child Neurol*. 2005;47:403–7. PubMed PMID: 15938069.
- DiDomenico P, Berry G, Bass D, Fridge J, Sarwal M. Noncirrhotic portal hypertension in association with juvenile nephropathic cystinosis: case presentation and review of the literature. *J Inherit Metab Dis*. 2004;27:693–9. PubMed PMID: 15669688.
- Dogulu CF, Tsilou E, Rubin B, Fitzgibbon EJ, Kaiser-Kupper MI, Rennert OM, Gahl WA. Idiopathic intracranial hypertension in cystinosis. *J Pediatr*. 2004;145:673–8. PubMed PMID: 15520772.
- Dohil R, Newbury RO, Sellers ZM, Deutsch R, Schneider JA. The evaluation and treatment of gastrointestinal disease in children with cystinosis receiving cysteamine. *J Pediatr*. 2003;143:224–30. PubMed PMID: 12970638.
- Freed KA, Blangero J, Howard T, Johnson MP, Curran JE, Garcia YR, Lan HC, Abboud HE, Moses EK. The 57 kb deletion in cystinosis patients extends into TRPV1 causing dysregulation of transcription in peripheral blood mononuclear cells. *J Med Genet*. 2011;48:563–6. PubMed PMID: 21546516.
- Gahl WA, Balog J, Kleta R. Nephropathic cystinosis in adults: natural history and effect of oral cysteamine therapy. *Ann Intern Med*. 2007;147:242–50. PubMed PMID: 17709758.
- Gahl WA, Kuehl EM, Iwata F, Lindblad A, Kaiser-Kupfer MI. Corneal crystals in nephropathic cystinosis: natural history and treatment with cysteamine eyedrops. *Mol Genet Metab*. 2000;71:100–20. PubMed PMID: 11001803.
- Gahl WA, Thoene JG, Schneider JA. Cystinosis. *N Engl J Med*. 2002;347:111–21. PubMed PMID: 12110740.
- Gahl WA, Thoene JG, Schneider JA. Cystinosis: A disorder of lysosomal membrane transport. In: Scriver CR, Beaudet AL, Sly WS, Valle D, Vogelstein B, eds. *The Metabolic and Molecular Bases of Inherited Disease*. 8 ed. New York, NY: McGraw-Hill; 2001:5085–108.
- Haase M, Morgera S, Bamberg C, Halle H, Martini S, Dragun D, Neumayer H-H, Budde K. Successful pregnancies in dialysis patients including those suffering from cystinosis and familial Mediterranean fever. *J Nephrol*. 2006;19:677–81. PubMed PMID: 17136701.
- Ivanova EA, Arcolino FO, Elmonem MA, Rastaldi MP, Giardino L, Cornelissen EM, van den Heuvel LP, Levtchenko EN. Cystinosin deficiency causes podocyte damage and loss associated with increased cell motility. *Kidney Int*. 2016;89:1037–48. PubMed PMID: 27083281.
- Ivanova EA, De Leo MG, Van Den Heuvel L, Pastore A, Dijkman H, De Matteis MA, Levtchenko EN. Endo-lysosomal dysfunction in human proximal tubular epithelial cells deficient for lysosomal cystine transporter cystinosin. *PLoS One*. 2015;10:e0120998. PubMed PMID: 25811383.

- Kaiser-Kupfer MI, Fujikawa L, Kuwabara T, Jain S, Gahl WA. Removal of corneal crystals by topical cysteamine in nephropathic cystinosis. *N Engl J Med*. 1987;316:775–9. PubMed PMID: 3821824.
- Kalatzis V, Antignac C. Cystinosis: from gene to disease. *Nephrol Dial Transplant*. 2002;17:1883–6. PubMed PMID: 12401840.
- Kalatzis V, Antignac C. New aspects of the pathogenesis of cystinosis. *Pediatr Nephrol*. 2003;18:207–15. PubMed PMID: 12644911.
- Kalatzis V, Cohen-Solal L, Cordier B, Frishberg Y, Kemper M, Nuutinen EM, Legrand E, Cochat P, Antignac C. Identification of 14 novel CTNS mutations and characterization of seven splice site mutations associated with cystinosis. *Hum Mutat*. 2002;20:439–46. PubMed PMID: 12442267.
- Kiehntopf M, Schickel J, Gonne B, Koch HG, Superti-Furga A, Steinmann B, Deufel T, Harms E. Analysis of the CTNS gene in patients of German and Swiss origin with nephropathic cystinosis. *Hum Mutat*. 2002;20:237. PubMed PMID: 12204010.
- Kleta R. A deeper look into cysteamine absorption for the treatment of cystinosis. *J Pediatr*. 2006;148:718–9. PubMed PMID: 16769374.
- Kleta R, Anikster Y, Lucero C, Shotelersuk V, Huizing M, Bernardini I, Park M, Thoene J, Schneider J, Gahl WA. CTNS mutations in African American patients with cystinosis. *Mol Genet Metab*. 2001;74:332–7. PubMed PMID: 11708862.
- Kleta R, Bernardini I, Ueda M, Varade WS, Phornphutkul C, Krasnewich D, Gahl WA. Long-term follow-up of well-treated nephropathic cystinosis patients. *J Pediatr*. 2004a;145:555–60. PubMed PMID: 15480385.
- Kleta R, Blair SC, Bernardini I, Kaiser-Kupfer MI, Gahl WA. Keratopathy of multiple myeloma masquerading as corneal crystals of ocular cystinosis. *Mayo Clin Proc*. 2004b;79:410–2. PubMed PMID: 15008615.
- Kleta R, Gahl WA. Cystinosis: antibodies and healthy bodies. *J Am Soc Nephrol*. 2002;13:2189–91. PubMed PMID: 12138155.
- Kleta R, Gahl WA. Pharmacological treatment of nephropathic cystinosis with cysteamine. *Expert Opin Pharmacother*. 2004;5:2255–62. PubMed PMID: 15500372.
- Kleta R, Kaskel F, Dohil R, Goodyer P, Guay-Woodford LM, Harms E, Ingelfinger JR, Koch VH, Langman CB, Leonard MB, Mannon RB, Sarwal M, Schneider JA, Skovby F, Sonies BC, Thoene JG, Trauner DA, Gahl WA. First NIH/Office of Rare Diseases Conference on Cystinosis: past, present, and future. *Pediatr Nephrol*. 2005;20:452–4. PubMed PMID: 15747161.
- Langman CB, Greenbaum LA, Sarwal M, Grimm P, Niaudet P, Deschênes G, Cornelissen E, Morin D, Cochat P, Matossian D, Gaillard S, Bagger MJ, Rioux P. A randomized controlled crossover trial with delayed-release cysteamine bitartrate in nephropathic cystinosis: effectiveness on white blood cell cystine levels and comparison of safety. *Clin J Am Soc Nephrol*. 2012;7:1112–20. PubMed PMID: 22554716.
- Larsen CP, Walker PD, Thoene JG. The incidence of atubular glomeruli in nephropathic cystinosis renal biopsies. *Mol Genet Metab*. 2010;101:417–20. PubMed PMID: 20826102.
- Macías-Vidal J, Rodés M, Hernández-Pérez JM, Vilaseca MA, Coll MJ. Analysis of the CTNS gene in 32 cystinosis patients from Spain. *Clin Genet*. 2009;76:486–9. PubMed PMID: 19863563.
- Mahoney CP, Striker GE. Early development of the renal lesions in infantile cystinosis. *Pediatr Nephrol*. 2000;15:50–6. PubMed PMID: 11095011.
- Markello TC, Bernardini IM, Gahl WA. Improved renal function in children with cystinosis treated with cysteamine. *N Engl J Med*. 1993;328:1157–62. PubMed PMID: 8455682.
- Mason S, Pepe G, Dall'Amico R, Tartaglia S, Casciani S, Greco M, Bencivenga P, Murer L, Rizzoni G, Tenconi R, Clementi M. Mutational spectrum of the CTNS gene in Italy. *Eur J Hum Genet*. 2003;11:503–8. PubMed PMID: 12825071.

- McGowan-Jordan J, Stoddard K, Podolsky L, Orrbine E, McLaine P, Town M, Goodyer P, MacKenzie A, Heick H. Molecular analysis of cystinosis: probable Irish origin of the most common French Canadian mutation. *Eur J Hum Genet*. 1999;7:671–8. PubMed PMID: 10482956.
- Middleton R, Bradbury M, Webb N, O'Donoghue D, Van't Hoff W. Cystinosis. A clinicopathological conference. "From toddlers to twenties and beyond" Adult-Paediatric Nephrology Interface Meeting, Manchester 2001. *Nephrol Dial Transplant*. 2003;18:2492–5. PubMed PMID: 14605270.
- Nesterova G, Gahl W. Nephropathic cystinosis: late complications of a multisystemic disease. *Pediatr Nephrol*. 2008;23:863–78. PubMed PMID: 18008091.
- Nesterova G, Williams C, Bernardini I, Gahl WA. Cystinosis: renal glomerular and renal tubular function in relation to compliance with cystine-depleting therapy. *Pediatr Nephrol*. 2015;30:945–51. PubMed PMID: 25526929.
- O'Brien K, Hussain N, Warady BA, Kleiner DE, Kleta R, Bernardini I, Heller T, Gahl WA. Nodular regenerative hyperplasia and severe portal hypertension in cystinosis. *Clin Gastroenterol Hepatol*. 2006;4:387–94. PubMed PMID: 16527704.
- Osefo N, Ito T, Jensen RT. Gastric acid hypersecretory states: recent insights and advances. *Curr Gastroenterol Rep*. 2009;11:433–41. PubMed PMID: 19903418.
- Park M, Helip-Wooley A, Thoene J. Lysosomal cystine storage augments apoptosis in cultured human fibroblasts and renal tubular epithelial cells. *J Am Soc Nephrol*. 2002;13:2878–87. PubMed PMID: 12444206.
- Phornphutkul C, Anikster Y, Huizing M, Braun P, Brodie C, Chou JY, Gahl WA. The promoter of a lysosomal membrane transporter gene, CTNS, binds Sp-1, shares sequences with the promoter of an adjacent gene, CARKL, and causes cystinosis if mutated in a critical region. *Am J Hum Genet*. 2001;69:712–21. PubMed PMID: 11505338.
- Ramappa AJ, Pyatt JR. Pregnancy-associated cardiomyopathy occurring in a young patient with nephropathic cystinosis. *Cardiol Young*. 2010;20:220–2. PubMed PMID: 20199711.
- Sansanwal P, Li L, Hsieh SC, Sarwal MM. Insights into novel cellular injury mechanisms by gene expression profiling in nephropathic cystinosis. *J Inherit Metab Dis*. 2010;33:775–86. PubMed PMID: 20865335.
- Schneider JA. Treatment of cystinosis: simple in principle, difficult in practice. *J Pediatr*. 2004;145:436–8. PubMed PMID: 15480361.
- Servais A, Morinière V, Grünfeld JP, Noël LH, Goujon JM, Chadeaux-Vekemans B, Antignac C. Late-onset nephropathic cystinosis: clinical presentation, outcome, and genotyping. *Clin J Am Soc Nephrol*. 2008;3:27–35. PubMed PMID: 18178779.
- Shotelersuk V, Larson D, Anikster Y, McDowell G, Lemons R, Bernardini I, Guo J, Thoene J, Gahl WA. CTNS mutations in an American-based population of cystinosis patients. *Am J Hum Genet*. 1998;63:1352–62. PubMed PMID: 9792862.
- Sonies BC, Almajid P, Kleta R, Bernardini I, Gahl WA. Swallowing dysfunction in 101 patients with nephropathic cystinosis: benefit of long-term cysteamine therapy. *Medicine (Baltimore)*. 2005;84:137–46. PubMed PMID: 15879904.
- Spilkin AM, Ballantyne AO, Babchuck LR, Trauner DA. Non-verbal deficits in young children with a genetic metabolic disorder: WPPSI-III performance in cystinosis. *Am J Med Genet B Neuropsychiatr Genet*. 2007;144B:444–7. PubMed PMID: 17471495.
- Thoene J, Lemons R, Anikster Y, Mullet J, Paelicke K, Lucero C, Gahl W, Schneider J, Shu SG, Campbell HT. Mutations of CTNS causing intermediate cystinosis. *Mol Genet Metab*. 1999;67:283–93. PubMed PMID: 10444339.
- Thoene JG. Cystinosis. *J Inherit Metab Dis*. 1995;18:380–6. PubMed PMID: 7494397.

- Touchman JW, Anikster Y, Dietrich NL, Maduro VV, McDowell G, Shotelersuk V, Bouffard GG, Beckstrom-Sternberg SM, Gahl WA, Green ED. The genomic region encompassing the nephropathic cystinosis gene (CTNS): complete sequencing of a 200-kb segment and discovery of a novel gene within the common cystinosis-causing deletion. *Genome Res.* 2000;10:165–73. PubMed PMID: 10673275.
- Town M, Jean G, Cherqui S, Attard M, Forestier L, Whitmore SA, Callen DF, Gribouval O, Broyer M, Bates GP, van't Hoff W, Antignac C. A novel gene encoding an integral membrane protein is mutated in nephropathic cystinosis. *Nat Genet.* 1998;18:319–24. PubMed PMID: 9537412.
- Trauner DA, Fahmy RF, Mishler DA. Oral motor dysfunction and feeding difficulties in nephropathic cystinosis. *Pediatr Neurol.* 2001;24:365–8. PubMed PMID: 11516611.
- Tsilou E, Zhou M, Gahl W, Sieving PC, Chan CC. Ophthalmic manifestations and histopathology of infantile nephropathic cystinosis: report of a case and review of the literature. *Surv Ophthalmol.* 2007;52:97–105. PubMed PMID: 17212992.
- Tsilou ET, Rubin BI, Reed G, Caruso RC, Iwata F, Balog J, Gahl WA, Kaiser-Kupfer MI. Nephropathic cystinosis: posterior segment manifestations and effects of cysteamine therapy. *Ophthalmology.* 2006;113:1002–9. PubMed PMID: 16603246.
- Tsilou ET, Rubin BI, Reed GF, Iwata F, Gahl W, Kaiser-Kupfer MI. Age-related prevalence of anterior segment complications in patients with infantile nephropathic cystinosis. *Cornea.* 2002;21:173–6. PubMed PMID: 11862089.
- Ueda M, O'Brien K, Rosing D, Ling A, Kleta R, McAreavey D, Bernardini I, Gahl W. Coronary artery and other vascular calcifications in patients with cystinosis after kidney transplantation. *Clin J Am Soc Nephrol.* 2006;1:555–62. PubMed PMID: 17699259.
- Veys KR, D'Hauwers KW, van Dongen AJ, Janssen MC, Besouw MT, Goossens E, van den Heuvel LP, Wetzels AA, Levtchenko EN. First successful conception induced by a male cystinosis patient. *JIMD Rep.* 2018;38:1–6. PubMed PMID: 28405942.
- Wamelink MM, Struys EA, Jansen EE, Blom HJ, Vilboux T, Gahl WA, Kömhoff M, Jakobs C, Levtchenko EN. Elevated concentrations of sedoheptulose in bloodspots of patients with cystinosis caused by the 57-kb deletion: implications for diagnostics and neonatal screening. *Mol Genet Metab.* 2011;102:339–42. PubMed PMID: 21195649.
- Wilmer MJ, Emma F, Levtchenko EN. The pathogenesis of cystinosis: mechanisms beyond cystine accumulation. *Am J Physiol Renal Physiol.* 2010;299:F905–16. PubMed PMID: 20826575.
- Wilmer MJ, Kluijtmans LA, van der Velden TJ, Willems PH, Scheffer PG, Masereeuw R, Monnens LA, van den Heuvel LP, Levtchenko EN. Cysteamine restores glutathione redox status in cultured cystinotic proximal tubular epithelial cells. *Biochim Biophys Acta.* 2011;1812:643–51. PubMed PMID: 21371554.
- Wühl E, Haffner D, Offner G, Broyer M, van't Hoff W, Mehls O, et al. Long-term treatment with growth hormone in short children with nephropathic cystinosis. *J Pediatr.* 2001;138:880–7. PubMed PMID: 11391333.
- Yeagy BA, Harrison F, Gubler MC, Koziol JA, Salomon DR, Cherqui S. Kidney preservation by bone marrow cell transplantation in hereditary nephropathy. *Kidney Int.* 2011;79:1198–206. PubMed PMID: 21248718.
- Zimakas PJ, Sharma AK, Rodd CJ. Osteopenia and fractures in cystinotic children post renal transplantation. *Pediatr Nephrol.* 2003;18:384–90. PubMed PMID: 12700967.

Chapter Notes

Author Notes

Dr Gahl is a pediatrician, medical geneticist, and biochemical geneticist who performs clinical and basic research into rare diseases. He has seen approximately 300 individuals with cystinosis and published more than 85 articles and reviews on the subject.

Author History

William A Gahl, MD, PhD (2001-present)

Robert Kleta, MD, PhD; National Human Genome Research Institute (2001-2009)

Galina Nesterova, MD (2009-present)

Revision History

- 7 December 2017 (ma) Revision: information from Veys et al 2017
- 6 October 2016 (sw) Comprehensive update posted live
- 30 January 2014 (me) Comprehensive update posted live
- 17 May 2012 (cd) Revision: to include deletion/duplication analysis for identification of deletions/duplications in addition to the common 57-kb deletion
- 11 August 2011 (me) Comprehensive update posted live
- 9 April 2009 (me) Comprehensive update posted live
- 18 October 2005 (me) Comprehensive update posted live
- 6 June 2003 (ca) Comprehensive update posted live
- 22 March 2001 (me) Review posted live
- January 2001 (wg) Original submission

Note: Pursuant to 17 USC Section 105 of the United States Copyright Act, the *GeneReview* "Cystinosis" is in the public domain in the United States of America.

License

GeneReviews® chapters are owned by the University of Washington. Permission is hereby granted to reproduce, distribute, and translate copies of content materials for noncommercial research purposes only, provided that (i) credit for source (<http://www.genereviews.org/>) and copyright (© 1993-2020 University of Washington) are included with each copy; (ii) a link to the original material is provided whenever the material is published elsewhere on the Web; and (iii) reproducers, distributors, and/or translators comply with the [GeneReviews® Copyright Notice and Usage Disclaimer](#). No further modifications are allowed. For clarity, excerpts of GeneReviews chapters for use in lab reports and clinic notes are a permitted use.

For more information, see the [GeneReviews® Copyright Notice and Usage Disclaimer](#).

For questions regarding permissions or whether a specified use is allowed, contact: admasst@uw.edu.