

# Nitisinone-Induced Keratopathy in Alkaptonuria Disease: A Case Report and Literature Review

KHALID MOUSA AL ZUBI<sup>1</sup>, MOHAMMED SALEM ALSBOU<sup>2</sup>, MAHMOUD HUSSEIN ALKHASAWNEH<sup>3</sup>, HANI MOSLEH AL-SHAGAHIN<sup>4</sup>

## ABSTRACT

We report a case of nitisinone-induced keratopathy in a 52-year-old male patient with Alkaptonuria (AKU) disease in Jordan. The patient presented with slight drop of left eye vision for the last four weeks, associated with a foreign body sensation in his left eye. On examination, it was found that his left eye vision was reduced to 6/12 and there were left dendrite-like corneal opacities in the left eye. He was given 10 mg of nitisinone per day, two years before his visual complaint. Three months following discontinuation of nitisinone, his visual acuity and corneal opacities disappeared completely. This is the fifth reported case of nitisinone-induced keratopathy, due to secondary tyrosinaemia in alkaptonuria.

**Keywords:** Pseudodendritic keratitis, Richner-Hanhart syndrome, Tyrosinaemia

## CASE REPORT

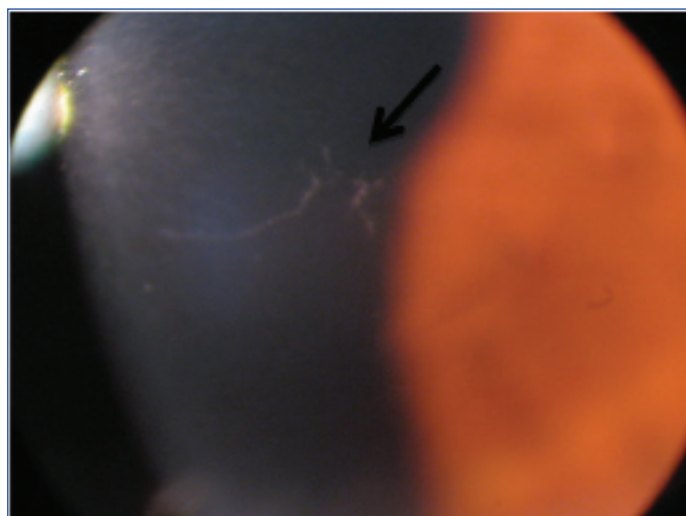
A 52-year-old male patient, known case of alkaptonuria, presenting to the Eye Center with a chief complaint of blurred vision and foreign body sensation in the left eye for the last four weeks from the date of presentation.

The patient had history of severe low back pain, morning stiffness, and pain in his both knees and hips 17 years prior to the present complaint. Clinical examination revealed a bluish-grey pigmentation of both ears. He had been passing dark urine since birth. His urine turned dark-black in colour upon standing for 24 hours. A transient blue colour was observed on performing Ferric chloride ( $\text{FeCl}_3$ ) test. This indicated a positive test and suggested the presence of Homogentisic Acid (HGA). Confirmation of diagnosis was done by quantitative measurement of HGA in 24 hour urine sample using Gas Chromatography Mass Spectrometry (GC-MS), which revealed a high level of HGA. The patient had a family history of AKU.

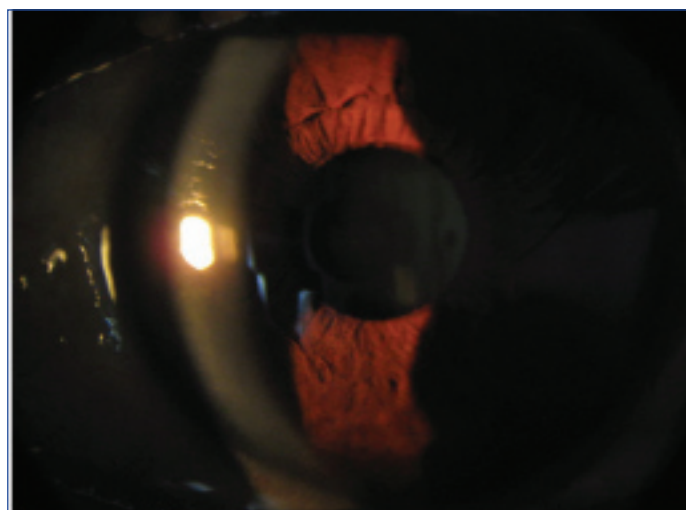
After obtaining an informed consent from the patient, he was started on 10 mg of nitisinone per day, two years prior to his chief complaint, but could not comply with a reduced protein diet while he was on nitisinone treatment. Clinical examination revealed, his best corrected visual acuity of the right eye was 6/6 and that of the left eye was 6/12. The right eye examination showed grey scleral pigmentation and a normal posterior segment. The left eye examination showed grey scleral pigmentation and there were dendrite-like corneal opacities [Table/Fig-1] with a few punctate epithelial erosions, with no other signs of active inflammatory or infective keratitis and left eye posterior segment was normal. The intraocular pressure was 16 mmHg in the right eye and 15 mmHg in the left eye. Examination of the corneal sensation was done and showed bilateral symmetrical and normal sensation.

A conjunctival swab was taken and polymerase chain reaction test did not reveal the presence of *Herpes simplex virus* and *Herpes zoster virus* infection. A blood sample was also taken and serum tyrosine level was 703.3  $\mu\text{mol/L}$  (reference range 30–90  $\mu\text{mol/L}$ ). So, after a thorough discussion with the patient, a decision was taken to stop the nitisinone treatment completely and he was started on sodium hyaluronate eye drop four times daily. Three months later, he was asymptomatic, with the best corrected visual acuity was 6/6

in both eyes, and his corneal opacities were completely resolved [Table/Fig-2]. Serum tyrosine level was also within normal limits at 76.6  $\mu\text{mol/L}$ .



[Table/Fig-1]: Slit lamp examination of the left eye plus slit lamp photography showing corneal opacities.



[Table/Fig-2]: Slit lamp examination of the left eye plus slit lamp photography showing resolved corneal opacities.

## DISCUSSION

Alkaptonuria is a very rare inherited metabolic disorder of tyrosine degradation, due to a genetic defect in the enzyme homogentisate dioxygenase, which result in high circulating Homogentisic Acid (HGA) [1,2]. Upon exposure to air, homogentisic acid is oxidized to form a pigment like polymeric material responsible for the black colour of urine. The homogentisic acid is rapidly cleared and excreted by the kidney, but over time it is accumulated and deposited in the connective tissues and converted to a pigment like polymer (ochronosis). This is a chronic process and the external signs of pigment deposition usually start to appear by the fourth decade of life. Ocular signs of alkaptonuria are the black or grey discolouration of the sclera which is the most common finding [3], oil-drop like pigmentation of the limbus which is slightly less common but pathognomonic for alkaptonuria, conjunctival pigmentation and increased conjunctival vessel diameter, severe progressive astigmatism [4,5], and anterior chamber angle hyperpigmentation which may cause secondary glaucoma [3].

The incidence rate of AKU is 1 in 250,000 in most populations. However, high incidence rates have been reported in some countries such as Slovakia (1 in 19,000) [6]. Previous studies have identified 73 cases with AKU in Jordan [7]. Forty cases were diagnosed in one village in the southern region of Jordan, two-third of the patients were young under the age of thirty and nine patients were affected with the disease in one family. The high incidence of AKU in Jordan is due to the high rate of consanguineous marriages [8,9].

Nitisinone (Orfadin; 2-(2-nitro-4 trifluoromethylbenzoyl)-1,3 cyclohexanedione) is an FDA-approved drug for the treatment of hereditary Tyrosinaemia type 1 (HT-1) [10] and it has been widely used at a high dose of 1-2 mg/kg/day in the treatment of this disease [1,11]. It is a new non-licensed treatment for alkaptonuria, which inhibits p-hydroxyphenyl pyruvate dioxygenase, the enzyme leading to the formation of HGA. So, it can drastically reduce urinary excretion of HGA and also reduce HGA in plasma, in individuals with alkaptonuria [12,13].

This mode of action will lead to the increase of the circulating tyrosine (secondary Tyrosinaemia) [1,14]. Tyrosinaemia can be classified into three types: 'Hereditary Infantile Tyrosinaemia' (Tyrosinaemia I), 'Richner-Hanhart Syndrome' (Tyrosinaemia II) and 'Tyrosinaemia III'.

The resulting secondary Tyrosinaemia due to the use of nitisinone is more likely to resemble Tyrosinaemia type II [15], where the corneal deposits and skin manifestations are the hallmark of this type.

Tyrosinaemia type II was first described by Richner H and nine years later by Hanhart E as an oculocutaneous syndrome [16,17]. It is a rare disease caused by a deficiency of hepatic Tyrosine Aminotransferase (TAT) with an autosomal recessive mode of inheritance, resulting in elevated plasma and urinary tyrosine concentrations. It is usually characterized by painful palmoplantar hyperkeratotic lesions, bilateral pseudodendritic keratitis, mental retardation, and variable manifestations of central nervous system involvement [15].

Dendrite-like corneal opacities can be seen in Tyrosinaemia type I, Tyrosinemia II, Neurotrophic keratopathy, Recurrent Erosion Syndrome, contact lens use, corneal dystrophies and drug toxicity [16-20].

This is the fifth reported case of nitisinone-induced reversible keratopathy due to secondary Tyrosinaemia, the first and second cases were using 2mg/kg/day and 2mg every other day respectively. The third case showed that introducing a low protein diet with low dose of nitisinone was successful in controlling plasma tyrosine levels and the patient remained asymptomatic [21]. However, asymptomatic dendritiform corneal keratopathy has been described with the use of low dose nitisinone in AKU in the fourth case [22]. The significant findings in the five reported cases of nitisinone-induced keratopathy in alkaptonuria disease is summarised in [Table/Fig-3].

Status of Corneal Findings	Skin Findings	Corneal Findings	Nitisinone Dose	Case Number and Reference
Reversible	None	Branching, sub-epithelial corneal opacities	2 mg daily	1. Introne WJ et al., [12]
Reversible	itchy urticarial skin rash	Dendritic keratopathy	2 mg on alternate days	2. Stewart RM et al., [1]
Reversible	None	Corneal crystalline keratopathy	0.5 mg daily	3. White A et al., [21]
Reversible	None	Asymptomatic dendritiform corneal keratopathy	2 mg daily	4. Khedr M et al., [22]
Reversible	None	Dendrite-like corneal opacities	10 mg daily	5. Present Study

**[Table/Fig-3]:** Reported cases of Nitisinone-induced Keratopathy in Alkaptonuria disease [1,12,21,22].

In all cases, the dendrite-like corneal deposits were completely reversible. Previous studies showed that the plasma tyrosine levels averaged 800  $\mu\text{mol/L}$ , in individuals using Nitisinone in AKU treatment and these tyrosine levels were remarkably well-tolerated [1]. But, in the first reported case using 2 mg of nitisinone per day, the plasma tyrosine level was 200  $\mu\text{mol/L}$ , which is far below the average level in treated individuals suggesting that there are other predisposing factors for the corneal toxicity. In our case the plasma tyrosine level was 703.3  $\mu\text{mol/L}$  on presentation which is around the average levels and it was 76.6  $\mu\text{mol/L}$  three months following discontinuation of the treatment when he was completely asymptomatic with disappearance of his left corneal opacities.

## CONCLUSION

Using nitisinone in the treatment of AKU is still not licensed, but it has a high efficacy in reducing the plasma and urine HGA. This mode of action will result in secondary Tyrosinaemia, especially if there was no restriction of protein intake. Dendrite-like corneal opacities can be seen in individuals using nitisinone, due to the secondary hypertyrosinaemia, but they are usually completely reversible upon discontinuation of the treatment. Thus, we need to be aware of this treatable complication and further research may be required to identify other predisposing factors, and an alternative treatment for AKU.

## REFERENCES

- [1] Stewart RM, Briggs MC, Jarvis JC, Gallagher JA, Ranganath L. Reversible keratopathy due to hypertyrosinaemia following intermittent low-dose nitisinone in alkaptonuria: a case report. *JIMD Reports*. 2014;17:1-6. Springer Berlin Heidelberg.
- [2] Phornphutkul C, Introne WJ, Perry MB, Bernardini I, Murphey MD, Fitzpatrick DL, et al. Natural history of alkaptonuria. *New England Journal of Medicine*. 2002;347(26):2111-21.
- [3] Lindner M, Bertelmann T. On the ocular findings in ochronosis: a systematic review of literature. *BMC ophthalmology*. 2014;14(1):12.
- [4] Ehongo A, Schrooyen M, Pereleux A. Important bilateral corneal astigmatism in a case of ocular ochronosis. *Bulletin de la Societe belge d'ophtalmologie*. 2005(295):17-21.
- [5] Cheskes J, Buettner H. Ocular manifestations of alkaptonuric ochronosis. *Archives of Ophthalmology*. 2000;118(5):724-25.
- [6] Sršen Š, Císárik F, Pásztor L, Harnecko L, Opitz JM. Alkaptonuria in the Trenčín District of Czechoslovakia. *American Journal of Medical Genetics Part A*. 1978;2(2):159-66.
- [7] Alajoulin OA, Alsou MS, Somayya O, Kalbouneh HM. Spontaneous Achilles tendon rupture in alkaptonuria. *Saudi Medical Journal*. 2015;36(12):1486.
- [8] Al-sbou M, Mwafi N, Lubad MA. Identification of forty cases with alkaptonuria in one village in Jordan. *Rheumatology International*. 2012;32(12):3737-40.
- [9] Al-sbou M, Mwafi N. Nine cases of Alkaptonuria in one family in southern Jordan. *Rheumatology international*. 2012;32(3):621-25.
- [10] Onojafe IF, Adams DR, Simeonov DR, Zhang J, Chan CC, Bernardini IM, et al. Nitisinone improves eye and skin pigmentation defects in a mouse model of oculocutaneous albinism. *The Journal of Clinical Investigation*. 2011;121(10):3914.

- [11] Lindstedt S, Holme E, Lock EA, Hjalmarson O, Strandvik B. Treatment of hereditary tyrosinaemia type I by inhibition of 4-hydroxyphenylpyruvate dioxygenase. *The Lancet*. 1992;340(8823):813-17.
- [12] Introne WJ, Perry MB, Troendle J, Tsilou E, Kayser MA, Suwannarat P, et al. A 3-year randomized therapeutic trial of nitisinone in alkaptonuria. *Molecular Genetics and Metabolism*. 2011;103(4):307-14.
- [13] Suwannarat P, O'Brien K, Perry MB, Sebring N, Bernardini I, Kaiser-Kupfer MI, et al. Use of nitisinone in patients with alkaptonuria. *Metabolism*. 2005;54(6): 719-28.
- [14] Lock EA, Ellis MK, Gaskin P, Robinson M, Auton TR, Provan WM, et al. From toxicological problem to therapeutic use: the discovery of the mode of action of 2-(2-nitro-4-trifluoromethylbenzoyl)-1,3-cyclohexanedione (NTBC), its toxicology and development as a drug. *Journal of Inherited Metabolic Disease*. 1998;21(5):498-506.
- [15] Tsai CP, Lin PY, Lee NC, Niu DM, Lee SM, Hsu WM. Corneal lesion as the initial manifestation of Tyrosinaemia type II. *Journal of the Chinese Medical Association*. 2006;69(6):286-88.
- [16] Ahmad S, Teckman JH, Lueder GT. Corneal opacities associated with NTBC treatment. *American Journal of Ophthalmology*. 2002;134(2):266-68.
- [17] Iskeleli G, Bilgeç MD, Arici C, Atalay E, Oğreden T, Aydın A. Richner-Hanhart syndrome (Tyrosinaemia type II): a case report of delayed diagnosis with pseudodendritic corneal lesion. *Turk J Pediatr*. 2011;53(6):692-94.
- [18] Starck T, Kenyon KR, Hanninen LA, Beyer-Machule C, Fabian R, Gorn RA, et al. Clinical and histopathologic studies of two families with lattice corneal dystrophy and familial systemic amyloidosis (Meretoja syndrome). *Ophthalmology*. 1991;98(8):1197-206.
- [19] Sevim DG, Gumus K, Cavanagh HD. Corneal pseudodendritic lesions masquerading as herpetic keratitis in a patient with Tyrosinaemia type I. *Eye & Contact Lens*. 2017;43(3):e7-9.
- [20] Basu PK. Toxic effects of drugs on the corneal epithelium: a review. *Journal of Toxicology: Cutaneous and Ocular Toxicology*. 1983;2(4-5):205-27.
- [21] White A, Tchan MC. Nitisinone-Induced Keratopathy in Alkaptonuria: A Challenging Diagnosis Despite Clinical Suspicion. In *JIMD Reports*, 2017 (pp.1-3). Springer, Berlin, Heidelberg.
- [22] Khedr M, Judd S, Briggs MC, Hughes AT, Milan AM, Stewart RM, et al. Asymptomatic Corneal Keratopathy Secondary to Hypertyrosinaemia Following Low Dose Nitisinone and a Literature Review of Tyrosine Keratopathy in Alkaptonuria. *JIMD Reports*, 2017 (pp. 1-7). Springer, Berlin, Heidelberg.

#### PARTICULARS OF CONTRIBUTORS:

1. Assistant Professor, Special Surgery, Mutah University, Amman, Jordan.
2. Associate Professor, Pharmacology, Mutah University, Amman, Jordan.
3. Assistant Professor, Radiology, Mutah University, Amman, Jordan.
4. Associate Professor, Special Surgery, Mutah University, AlKarak, Amman, Jordan.

#### NAME, ADDRESS, E-MAIL ID OF THE CORRESPONDING AUTHOR:

Dr. Khalid Mousa Al Zubi,  
Assistant Professor, Special Surgery, Mutah University, P.O.Box 1342, Amman, Jordan.  
E-mail: dr\_khalid\_zu@yahoo.com

**FINANCIAL OR OTHER COMPETING INTERESTS:** None.

Date of Submission: **Jan 26, 2018**

Date of Peer Review: **Mar 20, 2018**

Date of Acceptance: **Apr 23, 2018**

Date of Publishing: **Jun 01, 2018**

Copyright of Journal of Clinical & Diagnostic Research is the property of JCDR Research & Publications Private Limited and its content may not be copied or emailed to multiple sites or posted to a listserv without the copyright holder's express written permission. However, users may print, download, or email articles for individual use.